

Original Research Paper

# Assessment of the Influence of Dust-Salt Aerosols of the Aral Sea on the Morphological Characteristics of the Tissue of the Epididymis of Rats in the Experiment

<sup>1,2</sup>Assylgul Suleimen, <sup>2</sup>Bibigul Rakhimova, <sup>2</sup>Svetlana Jangildinova, <sup>1</sup>Aidar Aitkulov, <sup>2</sup>Bayan Yessilbayeva, <sup>2</sup>Bayan Dyussenbekova, <sup>3</sup>Michael Danilenko and <sup>2</sup>Nursaya Beygam

<sup>1</sup>Department of Physiology, E.A. Buketov Karaganda University, Karaganda, Kazakhstan

<sup>2</sup>Department of Biomedicine, Karaganda Medical University, Karaganda, Kazakhstan

<sup>3</sup>Department of Clinical Biochemistry and Pharmacology, Ben-Gurion University of the Negev: Beer-Sheva, Israel

## Article history

Received: 19-04-2024

Revised: 30-05-2024

Accepted: 03-06-2024

## Corresponding Author:

Bibigul Rakhimova  
Department of Biomedicine,  
Karaganda Medical University,  
Karaganda, Kazakhstan  
Email: RahimovaB@qmu.kz

**Abstract:** Drying of the Aral Sea is a very significant environmental problem of modern times. Dust particles from the dried seabed are spread over long distances and negatively impact the quality of life of residents in nearby areas. One of the significant problems is the decrease in the fertility of residents of the Aral region, but there is insufficient data about the influence of dust-salt aerosols on the functioning of the reproductive organs of men. We assessed the influence of dust particles from the dried bed of the Aral Sea on the microstructure and some morphometric parameters (tubule diameter and height of epithelium) of the epididymis of rats. In this experimental study, 21 white rats (males) were divided into the following three groups: The first experimental group with a duration of inhalation exposure of seven days and the second experimental group with inhalation of seventy-two days. Inhalation exposure for the white laboratory male rats was conducted for 4 h daily for both experimental groups. For administration purposes, a fine aerosol composed of particles from the dried part of the Aral Sea was employed. The animals were exposed to a toxic dose of sodium chloride (the main component in the aerosol) amounting to 1.5 mg/m<sup>3</sup>. After the completion of the inhalation exposure, the experimental animals were fixed, epididymides were removed and stained. The microstructure of stained epididymis preparations of the rats from the control and experimental groups was examined in comparison. In the experimental groups, after inhalational exposure to dust-salt aerosols from the Aral Sea, interstitial edema and deterioration in the hemodynamics of the epididymis, destructive changes in the lumen of the tubules, decrease in the height of the epididymal epithelium, a reduction in the number and uneven distribution of spermatozoa in the tubules were observed. Short-term and long-term exposure to dust particles from the dried part of the Aral Sea can cause reproductive dysfunction due to damage to the tissues of the epididymis and disruption of sperm maturation.

**Keywords:** Dust-Salt Aerosols, Aral Sea, Inhalation Exposure, Rat, Epididymis

## Introduction

The drying of the Aral Sea represents significant environmental and socio-economic challenges of the 20<sup>th</sup> century, a consequence of pursuing economic gains while disregarding potential negative environmental impacts. This crisis has unfolded over five decades, resulting in a 26.7-meter drop in sea level, a 7-8-fold reduction in water surface area and a volume decrease of 12-13 times. The parched

seabed has become a source of both dust and salt dispersion, contributing to the desertification of around 1.4 million hectares within the Aral Sea vicinity. These factors have given rise to severe adverse repercussions on the environment, society, economics, demographics and medical-biological aspects of the region (Novikova, 2019).

Among the significant environmental factors affecting public health, the dust-salt aerosols emanating from the Aral Sea play a paramount role. Laden with pesticides,

heavy metal salts and herbicides, these aerosols release tens of millions of tons of dust particles into the atmosphere annually from the Aral Sea floor (Wahler and Dietrichs, 2017). Alarming health statistics have emerged from the Aral Sea region, with over 70% of adults and 80% of children diagnosed with one or more illnesses, leading to a continuous decline in average life expectancy. Particularly vulnerable are those dwelling in areas stricken by this ecological catastrophe, displaying heightened relative risk for diseases such as atherosclerosis, coronary heart disease and arterial hypertension (Otarbaeva *et al.*, 2020). Additionally, dire environmental conditions have given rise to elevated infant mortality rates, growth stunting and a surge in kidney, liver and lung diseases. Notably, significant alterations in the presence of DNA oxidation products and fragments of RNA and DNA were observed in the biological fluids of the region's inhabitants (Jangildinova *et al.*, 2019a-b).

Presumably, the decline in the population of the region is explained not only by migration, high infant mortality and reduced life expectancy but also by impaired fertility in persons aged 18-45 years. It has been identified that women living in the Aral region tend to experience a later onset of menarche and premature menopause compared to women from environmentally safe regions of Kazakhstan (Turdybekova *et al.*, 2017). Additionally, one-third of women have been found to have inflammation of the reproductive organs and a quarter have experienced multiple spontaneous abortions or stillbirths throughout their lives (Turdybekova *et al.*, 2015). Experimental studies on the influence of sand particles from the Aral on the structure of rat ovaries revealed pathological deviations in the cortical layer of the ovaries, signs of disrupted folliculogenesis and post-ovulatory stage abnormalities in the ovarian cycle (Turdybekova *et al.*, 2018).

Studies on the reproductive health of men in the Aral region are scarce and do not fully explain the reasons for declining fertility rates. According to research, men living in the Aral crisis zone exhibit disruptions in the morpho-physiological characteristics of sperm and overall ejaculate quality (Kultanov *et al.*, 2015). Despite the limited number of studies on the reproductive health of men living in the Aral region, the results suggest that dust-salt aerosols may be associated with reduced male reproductive function.

In summary, dust-salt storms in the Aral region are a major factor affecting the health of the population, but there is insufficient data on their impact on men's reproductive health. When studying the effects of various substances on the reproductive system, the influence of toxicants on the epididymis is rarely assessed. Meanwhile, the epididymis is not only an excretory duct for ejaculation but also the site where sperm surface antigens mature, sperm concentrate and steroids and other

substances are produced that play an important role in maintaining the viability and activity of spermatozoa (Creasy, 2001). Therefore, alterations in the functions of the epididymis could be a cause of male fertility disorders.

The purpose of this experiment was to investigate the short-term and prolonged effects of dust-salt aerosols from the Aral Sea on the histological characteristics of the epididymis of rats in an experiment.

## Materials and Methods

### *Animals and Inhalation Administration*

The study included twenty-one outbred white male rats weighing 180-220 g. The animals were randomly divided into three groups (n = 7). Fourteen animals were included in the experimental groups, while seven rats constituted the control group without inhalation exposure. The experimental group was further subdivided into two parts: The first part underwent inhalation exposure for seven days to examine short-term effects and the second part underwent administration for 72 days to assess cumulative long-term effects. All animals were housed in a well-equipped vivarium with natural day and night cycles and a temperature range of 22-23°C, providing food and water in accordance with the main standards of the European Convention for the protection of animals used for scientific purposes (Directive, 2010). The study design was reviewed and approved by the ethics committee of Karaganda Medical University (protocol no. 6).

Inhalation exposure for the white laboratory male rats was conducted for 4 h daily, following the method established by Borisova *et al.* (1997). The device for animal inhalation exposure consisted of a cylindrical chamber with a volume of 0.155 m<sup>3</sup>, a loading funnel with a dispenser, fans and an automatic dust concentration analyzer. Mink houses for animals were attached to the side walls of the exposure chamber (Ibrayeva *et al.*, 2012).

For administration purposes, a fine aerosol composed of dust particles from the dried bed of the Aral Sea was employed. The animals were exposed to a toxic dose of sodium chloride, calculated according to regulatory documents (DSM-70, 2022) and amounting to 1.5 mg/m<sup>3</sup>. The calculation of the dosage for exposure was based on sodium chloride, as its content in dust samples from the Aral Sea floor is the highest compared to other salts. The content of minor components in the dust samples from the Aral Sea floor is presented in Table 1. The analysis was performed using atomic absorption spectrometry (Varian AA 140 atomic absorption spectrophotometer, Australia).

**Table 1:** Content of minor components in the Aral Sea salt dust, mg/kg

| Chemical composition | %          | Chemical composition | %       |
|----------------------|------------|----------------------|---------|
| Sc                   | 0,0004     | Nb                   | 0,0008  |
| P43                  | eq <0,02   | Mo                   | 0,0012  |
| Sb                   | <0,0015    | Sn                   | ≤0,0001 |
| Mn                   | 0,015      | V                    | 0,0006  |
| Pb                   | 0,0005     | Li                   | 0,0025  |
| Ti                   | 0,04       | Cd                   | <0,0005 |
| Zr                   | 0,0025     | Cu                   | 0,006   |
| As                   | <0,003     | Yb                   | 0,00006 |
| Ga                   | 0,0001     | Y                    | 0,0006  |
| W                    | eq <0,0002 | Zn                   | ≤0,002  |
| Cr                   | 0,0008     | Ag                   | 0,08    |
| Ni                   | 0,0003     | Co                   | 0,0001  |
| Ge                   | <0,00005   | Sr                   | 0,04    |
| Bi                   | <0,00005   | B                    | <0,002  |
| Ba                   | 0,01       | Be                   | 0,00006 |

Note: Calculation: 1 ppm = 1 mg/kg = 1 g/t = 0.0001%

### Preparation and Examination of Epididymis Samples

After the completion of inhalation exposure, the animals from all groups were partially decapitated using ether anesthesia, which complied with the main principles outlined in the "international guiding principles for biomedical research involving animals" (CIOMS, 1985). The testes were fixed using Bouin's solution, which contains picric acid, formalin and glacial acetic acid in a ratio of 15:5:1 and Carnoy's fluid (ethanol 100% 60 mL, chloroform-30 mL, glacial acetic acid-10 mL).

After fixation, the testes were dissected and the epididymides were removed. The samples were washed from the fixative and water removal was performed in a tissue processor using five series of isopropanol of increasing concentration. The samples were then clarified in portions of a mixture consisting of mineral oil and isopropanol, followed by pure mineral oil. Infiltration with paraffin wax was carried out at a temperature of 58°C. The blocks were made using the Sakura tissue-Tek TEC-5 embedding station (Japan). Sections of thickness between 4 and 6 µm were crafted using a Sakura Accu-Cut® SRM™ 200 rotary microtome. The preparations were stained using hematoxylin-eosin and Feulgen staining. Permanent mounting of slides was conducted in the synthetic media "Histomount".

The histological structure of the epididymis preparations was studied at 40×, 100×, 200× and 400× magnification using a Nikon Eclipse Ci light microscope (Japan). Photographs were taken using a Nikon DS-Fi2 camera (Japan). Morphometric parameters, including the cross-sectional diameter of tubules and epithelial thickness in µm, were assessed as per the method established by Ukhov and Astrakhantsev (1983).

### Biometry and Morphometric Analysis

The animals in the experimental groups were weighed immediately after the inhalation exposure, while the weight of the control group rats was determined after the experiment was completed. The absolute (g) and relative (%) weights of the epididymides were also determined. The relative weight was calculated as the percentage ratio of the weight of the animal's epididymis to its total weight. The epididymal tubule diameter was determined on 15 randomly selected cross-sections with visibly rounded tubules. The epithelium height was measured in the same sections. To determine the average values, four measurements were taken at opposite ends of the section.

### Statistical Analysis

For the data analysis, the statistical software package "statistica" (version 8.0) was used. The distribution of the characteristics of the variables was assessed through the application of the Shapiro-Wilk test (W). Since the investigated parameters demonstrated adherence to the normal distribution, paired comparisons were performed using a student's t-test. During statistical processing, the arithmetic Mean (M) and the standard error of the mean (m) were calculated according to the standard methodology (Koichubekov, 2015). Differences between the means were considered statistically significant at a significance level of p<0.05.

### Results

Cross-sections of the testicular appendage in the control group reveal round tubules with a regular shape featuring pseudostratified columnar epithelium. The outline of the lumen is even and the epithelial cells are uniformly arranged. Tall ciliated cells are oriented towards the tubule's lumen, while smaller intercalated basal cells lie on the basal membrane. The epithelium is separated from the connective tissue by an intact basal membrane.

Under a light microscope, two types of cells can be distinguished in the rat testicular appendage's epithelium: Principal and basal cells. Principal cells are situated from the basal plate to the narrow luminal space of the tubules. The nuclei of these cells have an oval or elongated shape and are located within the basal half of the cell, roughly at the same level and closer to the cell center. Basal cells, situated on the basal membrane, are present in fewer numbers. The nuclei of these cells are relatively large, exhibiting a round or elongated shape, surrounded by a thin rim of cytoplasm.

An intriguing observation is the dense aggregation of spermatozoa within the luminal space of the tubules, visible across all fields of view in every histological section (Fig. 1). In the extratubular space of the interstitial connective tissue, individual moderately filled blood vessels are present. The adventitial sheath is dense and consists of fibrillar structures positioned adjacent to one another.

The epithelium of the tubules in this group is low and uniform, with an average height of 33.38  $\mu\text{m}$  and an average diameter of the tubules measuring 321.66  $\mu\text{m}$  (Table 2). Principal and basal cells were also the only epithelial cells found in this group.

In a series of cross-sections of the testicular appendage in the first experimental group, the morphological pattern is maintained, but changes are observed in some tubules (approximately 65%): These changes include epithelial cytoplasmic vacuolization and thinning of the epididymal epithelium within the tubule, along with focal invagination of the epithelium. The epithelium exhibits heterogeneity in height across histological sections, with areas of necrosis present. Some segments (about 15%) of the seminiferous tubules are heavily damaged, demonstrating the shedding of germ cells and spermatogenesis.

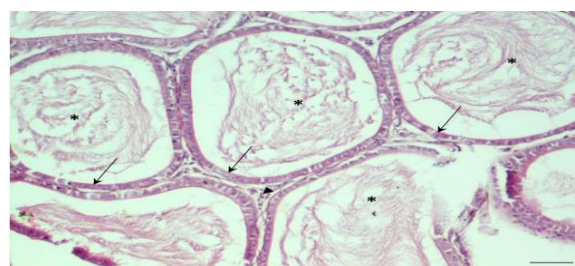
After seven days of inhalation with dust-salt aerosols, changes in the height of the tubular epithelium were noted. The epithelium's height in this group averaged 24.56  $\mu\text{m}$ , which is 26% less than in the control group (Table 2). In certain sections, the seminiferous tubules exhibit irregular outlines caused by epithelial damage and necrotic cell remnants. The displacement of cells into the lumen leads to a significant decrease in the proportion of epithelium, accompanied by a reduction in the tubule's lumen. The 7-day exposure to sea dust-salt aerosols led to a reduction of the tubular lumen's average diameter to 211.69  $\mu\text{m}$  (Table 2).

Connective tissues in most histological sections remained unaffected; however, blood vessels were dilated. The stroma is edematous and fibrous. The resulting interstitial edema is a result of fluid

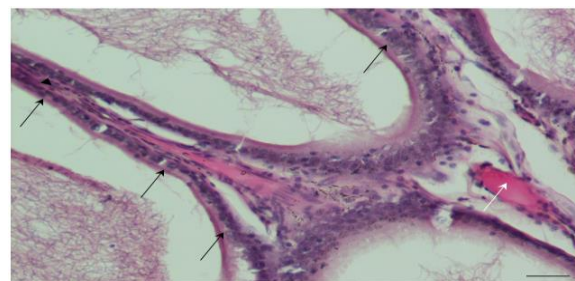
accumulation. The stroma contains single macrophages with granular cytoplasm and focal accumulations of granulocytes and lymphocytes. The capsule is edematous and blood vessels are full, with focal infiltration noted in some areas by cells with basophilic cytoplasm (Fig. 2).

In the most damaged tubules, a significantly lower number of spermatozoa was observed in comparison to the control group and in some tubules (10%), only single spermatozoa were present (Fig. 3).

The morphological pattern in the samples of the second experimental group is preserved, with sections of the seminiferous tubules identified in both transverse and longitudinal directions. Most of the tubules exhibit irregular shapes, but tubules of regular shape are also present.



**Fig. 1:** Control group. The histoarchitecture of the epididymis is preserved. The tubules are of a regular, rounded shape, containing numerous spermatozoa (black stars) in the lumen. The epithelial cells lining the epididymal duct (black arrows) range from cuboidal to flat shapes and have pyknotic nuclei. The epididymal tubules are compactly arranged and bounded by stroma (arrowhead). Hematoxylin-eosin staining,  $\times 100$

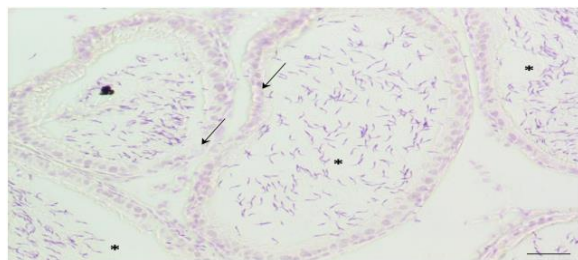


**Fig. 2:** First experimental group. The epithelium exhibits heterogeneous height (black arrows). Blood vessels are congested (white arrow). Increased interstitial space is observed (arrowhead). The stroma is edematous with scattered lymphohistiocytic infiltration. Hematoxylin-eosin staining,  $\times 200$

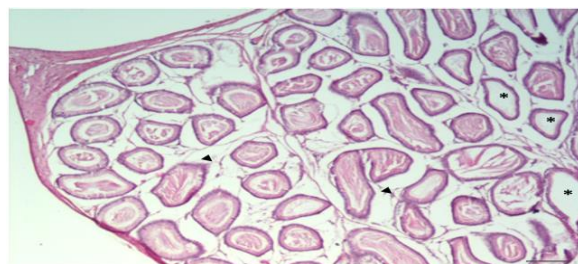
**Table 2:** Morphometric parameters of the epididymis of rats

| Morphometric parameters                                 | Control group      | I experimental group (7 days) | II experimental (72 days) |
|---|--------------------|-------------------------------|---------------------------|
| Epididymal tubule diameter, $\mu\text{m}$               | 321,66 $\pm$ 33,34 | 211,69 $\pm$ 47,81            | 262,13 $\pm$ 45,87        |
| Height of epididymal tubules' epithelium, $\mu\text{m}$ | 33,38 $\pm$ 3,07   | 24,56 $\pm$ 3,83              | 21,69 $\pm$ 3,53*         |
| Absolut epididymal weight, g                            | 1,35 $\pm$ 0,23    | 1,42 $\pm$ 0,31               | 1,24 $\pm$ 0,26           |
| Epididymal relative weight, %                           | 0,54 $\pm$ 0,08    | 0,88 $\pm$ 0,07*              | 0,56 $\pm$ 0,07           |

The reliability of differences between the experimental groups and analogous indicators of the control group,  $p < 0.01$



**Fig. 3:** First experimental group. Uneven distribution of tubules surrounded by stroma reduced epithelial height (black arrows) and a low number of spermatozoa was observed in the tubule lumen (black stars). Feulgen's stain,  $\times 200$

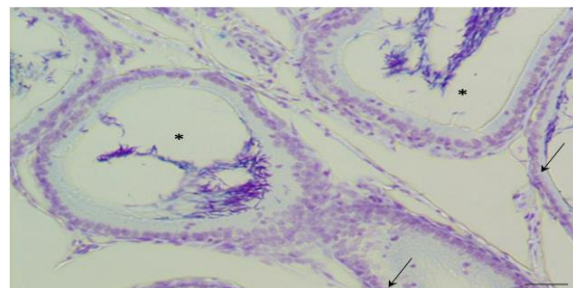


**Fig. 4:** Second experimental group. Distorted luminal changes in tubules, pronounced stromal edema (arrowheads) and absence of spermatozoa in some tubules (black stars). Hematoxylin-eosin staining,  $\times 40$

Hematoxylin-eosin staining of the testicular appendages in this group revealed heterogeneity in the seminiferous tubules, with disorganization and degeneration of the basement membrane in some tubules. In some tubules (less than 5%), damaged epithelial cells desquamated into the lumen of the tubules. Vacuoles appeared between the damaged cells, replacing them. In the lumen of certain tubules, a large number of sperm were observed. Some seminiferous tubules (less than 3%) were ruptured, with damage to the basement membrane. Additionally, interstitial expansion was noted, along with the appearance of vacuoles and plethoric blood vessels (Fig. 4).

The average thickness of the tubular epithelium in this group was  $21.69 \mu\text{m}$ , which significantly differs from that in the control group ( $33.38 \mu\text{m}$ ) and is similar to the average epithelium height in the first experimental group. Furthermore, prolonged exposure to sea dust-salt aerosols led to a constriction of the tubular lumen's average diameter to  $262.13 \mu\text{m}$  (Table 2).

During histological examination using the Feulgen stain, a moderate amount of unevenly distributed spermatozoa was identified in the lumen of the tubules in the second experimental group (Fig. 5). The number of spermatozoa in the tubule's lumen was lower than in the first experimental group and their distribution was less uniform than in the control group.



**Fig. 5:** Epithelium proliferation (black arrows), edematous stroma. A large number of sperm cells are unevenly distributed in the tubule lumen (black stars). Feulgen's stain,  $\times 200$

The average values of absolute epididymis weight did not statistically differ between the experimental groups and the control group. The average values of epididymal relative weight in the animals of the first experimental group (7 days of inhalation) were statistically significantly different from those in the control group (Table 2). On average, the relative epididymal weight in rats after seven days of inhalation exceeded that in the control group by 63%. There were no statistically significant differences in relative epididymal weight between the rats of the second experimental group (72 days of inhalation) and the control group.

## Discussion

Knowledge about the effect of air pollutants on epididymal function is limited. The reproductive toxicity of many substances has mainly been investigated through oral and intravenous exposures. However, pulmonary exposure to certain substances through inhalation can indirectly affect reproductive organs.

Negative effects of some inhaled air components on the functioning of the mouse epididymis have been demonstrated in experiments with formaldehyde (Köse *et al.*, 2012), allethrin-based mosquito coil smoke (Madhubabu and Yenugu, 2012), hexafluoroacetone (Lee and Kennedy, 1991), carbonaceous nanomaterials (Skovmand *et al.*, 2018), ethylene oxide (Mori *et al.*, 1991), methyl chloride (Chapin *et al.*, 1984), orthophthalaldehyde (Catlin *et al.*, 2018), sevoflurane (Zhang *et al.*, 2023), cigarette smoke (Abdul-Ghani *et al.*, 2014), nickel nanoparticles (Hu *et al.*, 2020), trichloroethylene (Kan *et al.*, 2007), airborne particulate matter (Qiu *et al.*, 2018) and diesel exhaust (Watanabe and Oonuki, 1999).

The most common structural abnormalities in the epididymis observed in these studies include epididymal atrophy and decreased epididymal weight Catlin *et al.*, Lee and Kennedy, Mori *et al.* Zhang *et al.*, increased sperm count in the epididymis (Abdul-Ghani *et al.*, 2014; Catlin *et al.*, 2018; Hu *et al.*, 2020; Köse *et al.*, 2012; Lee and Kennedy, 1991; Mori *et al.*, 1991; Qiu *et al.*, 2018; Watanabe and

Oonuki, 1999; Zhang *et al.*, 2023) and cellular apoptosis in the epididymis tissue Catlin *et al.*, Hu *et al.*, Zhang *et al.*, other observed changes include loss of tubule architecture, increased lumen size and large gaps in tubule lumens (Catlin *et al.*, 2018; Hu *et al.*, 2020; Madhubabu and Yenugu, 2012). In some cases, degeneration of epithelial cells, simplification of cell structure in the epithelium, disintegration of the basolateral cell membrane (Kan *et al.*, 2007; Madhubabu and Yenugu, 2012), vacuolization of epididymal cells (Kan *et al.*; Zhang *et al.*, 2023), bilateral epididymal granulomas (Chapin *et al.*, 1984) and interstitial edema (Madhubabu and Yenugu) have been reported. These changes are often attributed to the direct effects of airborne components penetrating the blood testis barrier and indirect effects via inflammation and increased oxidative stress, leading to reduced testosterone production.

Our study also observed typical signs of the negative impact of inhaled air components on the structure of rat epididymides. Histological examination of rat epididymides following a 7-day exposure to dust particles from the Aral Sea revealed severe dystrophic changes in the seminiferous tubule epithelium, diffuse lymphohistiocytic infiltration of the interstitium, marked vascular congestion and stromal edema. The presence of vacuoles in some cells and reduced spermatozoa count in the lumen indicated impaired spermatogenesis. The exposure also induced vascular dilation, ischemia and edema, which may be a direct consequence of altered hemodynamics due to vascular endothelial damage. The intense tissue edema in the epididymis of rats in the first experimental group, accompanied by a reduction in total body weight due to experimental stress conditions, is the most likely cause of the statistically significant increase in relative epididymal weight in the first experimental group of rats. Morphometric analysis confirmed a notable increase in empty intraepithelial spaces and a reduction in tubule diameter attributed to Aral Sea dust-salt aerosol exposure.

Prolonged exposure (72 days) to dust-salt aerosols led to further epididymal tissue damage, luminal distension, epithelial impairment and connective tissue loss. This extended exposure significantly exacerbated spermatogenesis disorders, evidenced by uneven sperm distribution and reduced sperm count within tubules compared to the control and initial experimental groups.

Previous studies have established that Aral Sea dust-salt aerosols induce morphological and histological changes in the testes of animals (Suleimen *et al.*, 2020). The current study reinforces these findings by demonstrating more pronounced epithelial tissue pathology after extended aerosol exposure. Another study reported ultrastructural changes in the ovaries of female rats exposed to Aral Sea salt aerosols, observing

intracellular alterations, destruction, vessel necrosis, stromal fibrosis and dystrophic changes in primary follicle epithelium (Turdybekova *et al.*, 2018). Thus, the influence of Aral Sea dust-salt aerosols engenders pathological changes in reproductive organ structures for both sexes.

In conclusion, this investigation unveiled the adverse impact of Aral Sea dust-salt aerosols on rat testicular tissues and spermatogenesis. The experimental groups exhibited compromised appendage hemodynamics, luminal alterations, structural disarray, reduced epididymal epithelial height and uneven sperm distribution. Prolonged aerosol exposure exacerbated epididymal tissue damage. Collectively, both short-term and long-term exposure to Aral Sea dust and salt aerosols appear to trigger reproductive dysfunction by impairing epididymal tissues and disrupting sperm maturation.

## Conclusion

As a result of the study, the negative effect of dust-salt aerosols from the Aral Sea on the tissues of the rat epididymis was revealed. The experimental groups exhibited interstitial edema and deterioration in the hemodynamics of the epididymis, destructive changes in the lumen of the tubules, thinning of the tubular epithelium in the epididymis and a reduction in the number and uneven distribution of spermatozoa in the tubules. Longer exposure to dust-salt aerosols led to more pronounced damage to the epididymis tissues. Thus, both the long and short-term impacts of Aral Sea dust and salt aerosols can cause reproductive dysfunction due to damage to the epididymis tissues and disruption of sperm maturation.

The results of these studies can be used to implement measures to improve the reproductive health of men in the Aral region. However, more detailed studies are necessary to explain the negative effects of Aral dust-salt aerosols on the functioning of reproductive system organs.

## Acknowledgment

The authors thank the reviewers for their contribution to the peer evaluation of this study. Thanks are due to Professor Kultanov B. Zh. for help in experiment planning.

## Funding Information

The authors have not received any financial support or funding to report.

## Author's Contributions

**Assylgul Suleimen, Svetlana Jangildinova and Bibigul Rakhimova:** Concept development, experiment,

analysis and discussion of the results, preparation and editing of the manuscript of the article.

**Aidar Aitkulov, Bayan Dyussenbekova and Nursaya Beygam:** Research resource support.

**Bayan Yessilbayeva and Michael Danilenko:** Methodology development, statistical analysis.

## Ethics

This article is original and contains unpublished material. The corresponding author confirms that all of the other authors have read and approved the manuscript and that no ethical issues are involved. All authors declare that they have no conflict of interest.

## References

- Abdul-Ghani, R., Qazzaz, M., Dabdoub, N., Muhammad, R. & Abdul-Ghani, A.-S., (2014). Studies on Cigarette Smoke Induced Oxidative DNA Damage and Reduced Spermatogenesis in Rats. *Journal of Environmental Biology*, 35(5), 943–947.  
[http://www.jeb.co.in/journal\\_issues/201409\\_sep14/paper\\_25.pdf](http://www.jeb.co.in/journal_issues/201409_sep14/paper_25.pdf)
- Borisova, L. B., Mareeva, L. B., & Dosmagambetova, R. S. (1997). *Inhalation administration of dust to animals in a toxicological experiment*. Guidelines, Almaty, 1-17.
- Catlin, N. R., Willson, C. J., Creasy, D. M., Rao, D. B., Kissling, G. E., McIntyre, B. S., & Wyde, M. (2018). Differentiating between Testicular Toxicity and Sexual Immaturity in Ortho-phthalaldehyde Inhalation Toxicity Studies in Rats and Mice. *Toxicologic Pathology*, 46(7), 753–763.  
<https://doi.org/10.1177/0192623318801790>
- Chapin, R. E., White, R. D., Morgan, K. T., & Bus, J. S. (1984). Studies of lesions induced in the testis and epididymis of F-344 rats by inhaled methyl chloride. *Toxicology and Applied Pharmacology*, 76(2), 328–343.  
[https://doi.org/10.1016/0041-008x\(84\)90014-0](https://doi.org/10.1016/0041-008x(84)90014-0)
- Creasy, D. M. (2001). Pathogenesis of Male Reproductive Toxicity. *Toxicologic Pathology*, 29(1), 64–76.  
<https://doi.org/10.1080/019262301301418865>
- Directive 2010/63/EU of the European Parliament and of the Council of the EU on the Protection of Animals Used for Scientific Purposes (2010). <https://eur-lex.europa.eu/LexUriServ/LexUriServ>
- Hu, W., Yu, Z., Gao, X., Wu, Y., Tang, M., & Kong, L. (2020). Study on the damage of sperm induced by nickel nanoparticle exposure. *Environmental Geochemistry and Health*, 42(6), 1715–1724.  
<https://doi.org/10.1007/s10653-019-00364-w>
- CIOMS. (1985). *International guiding principles for biomedical research involving animals*. Altern Lab Anim.  
[https://doi.org/https://cir.nii.ac.jp/crid/1570291225800782848#citations\\_container](https://doi.org/https://cir.nii.ac.jp/crid/1570291225800782848#citations_container)
- DSM-70, K. R. (2022). *Order of the minister of health of the republic of Kazakhstan of December 8, 2020 no. Kr dsm-238/2020*. CIS. Legislation.  
<https://doi.org/https://cis-legislation.com/document.fwx?rgn=129019>
- Ibrayeva, L. K., Sraubayev, E. N., Pudov, A. M., Uzbekov, V. A., & Koigel'dinova, Sh. S. (2012). Device for Inhalation Exposure of Experimental Animals to Polymetallic Dusts (Patent No. 2009/0814.1). In *Patent* (No. 2009/0814.1).
- Jangildinova, S., Tatina, Y., Kaliyeva, G., Kuvatbaeva, K., & Beygam, N. (2019a). The Content of Extracellular Nucleic Acids in the Blood and Ejaculate of Men of Reproductive Age Living in the Ecologically Unfavourable Regions of the Aral Sea. *Open Access Macedonian Journal of Medical Sciences*, 7(8), 1388–1390.  
<https://doi.org/10.3889/oamjms.2019.273>
- Jangildinova, S., Ivassenko, S., Kelmyalene, A., Yessilbayeva, B., Dyussenbekova, B., & Kinayatov, M. (2019b). Determination of the Product of DNA Oxidation in the Blood of Women Living in the Sub-Aral Area. *Open Access Macedonian Journal of Medical Sciences*, 7(10), 1672–1674.  
<https://doi.org/10.3889/oamjms.2019.333>
- Kan, F. W., Forkert, P. G., & Wade, M. G. (2007). Trichloroethylene exposure elicits damage in epididymal epithelium and spermatozoa in mice. *Histology and Histopathology*, 22(9), 977–988.  
<https://doi.org/https://digitum.um.es/digitum/handle/10201/27631>
- Koichubekov, B. K. (2015). *Biostatistics: A Training Manual* (1<sup>st</sup> Ed., Vol. 152). Almaty: Evero.
- Köse, E., Sarsilmaz, M., Taş, U., Kavaklı, A., Türk, G., Özlem Dabak, D., Sapmaz, H., & Ögetürk, M. (2012). Rose oil inhalation protects against formaldehyde-induced testicular damage in rats. *Andrologia*, 44, 342–348.  
<https://doi.org/10.1111/j.1439-0272.2011.01187.x>
- Kultanov, B. Z., Dosmagambetova, R. S., Ivassenko, S. A., Tatina, Y. S., Kelmyalene, A. A., & Assenova, L. H. (2015). The Study of Cellular and Molecular Physiological Characteristics of Sperm in Men Living in the Aral Sea Region. *Open Access Macedonian Journal of Medical Sciences*, 4(1), 5–8.  
<https://doi.org/10.3889/oamjms.2016.007>
- Lee, K. P., & Kennedy, G. L. (1991). Testicular toxicity of rats exposed to hexafluoroacetone (HFA) for 90 days. *Toxicology*, 67(3), 249–265.  
[https://doi.org/10.1016/0300-483x\(91\)90027-x](https://doi.org/10.1016/0300-483x(91)90027-x)

- Madhubabu, G., & Yenugu, S. (2012). Effect of continuous inhalation of allethrin-based mosquito coil smoke in the male reproductive tract of rats. *Inhalation Toxicology*, 24(3), 143–152. <https://doi.org/10.3109/08958378.2011.649189>
- Mori, K., Kaido, M., Fujishiro, K., Inoue, N., Koide, O., Hori, H., & Tanaka, I. (1991). Dose dependent effects of inhaled ethylene oxide on spermatogenesis in rats. *Occupational and Environmental Medicine*, 48(4), 270–274. <https://doi.org/10.1136/oem.48.4.270>
- Novikova, N. M. (2019). The ekologue-geographical aspect of the Aral crisis. Part 1. Development of the Aral problem, its study, evaluation and development of the activities. *Ecosystems: Ecology and Dynamics*, 3(1), 5–66. <https://doi.org/10.24411/2542-2006-2019-10026>
- Otarbaeva, M. B., Battakova, S. B., Amanbekova, A. U., Grebeneva, O. V., & Gazalieva, Sh. M. (2020). Risk assessment of circulatory system diseases among the population of the Aral Sea region. *Atherosclerosis*, 16(1), 28–32. <https://doi.org/10.15372/ATER20200105>
- Qiu, L., Chen, M., Wang, X., Qin, X., Chen, S., Qian, Y., Liu, Z., Cao, Q., & Ying, Z. (2018). Exposure to Concentrated Ambient PM<sub>2.5</sub> Compromises Spermatogenesis in a Mouse Model: Role of Suppression of Hypothalamus-Pituitary-Gonads Axis. *Toxicological Sciences*, 162(1), 318–326. <https://doi.org/10.1093/toxsci/kfx261>
- Skovmand, A., Jacobsen Lauvås, A., Christensen, P., Vogel, U., Sørig Hougaard, K., & Goericke-Pesch, S. (2018). Pulmonary exposure to carbonaceous nanomaterials and sperm quality. *Particle and Fibre Toxicology*, 15(1), 1–12. <https://doi.org/10.1186/s12989-018-0242-8>
- Suleimen, A., Yesimova, R., Rakhimova, B., Suleimen, G., Yerubay, A., Britko, V., Aitkulov, A., & Berikbai Kultanov. (2020). The Impact of Dust and Salt Aerosols of the Aral Sea on the Tissues of Rat Testes in the Experiment. *Open Access Macedonian Journal of Medical Sciences*, 8(A), 452–456. <https://doi.org/10.3889/oamjms.2020.4575>
- Turdybekova, Y. G., Dosmagambetova, R. S., Zhanabayeva, S. U., Bublik, G. V., Kubayev, A. B., Ibraibekov, Z. G., Kopobayeva, I. L., & Kultanov, B. Zh. (2015). The Health Status of the Reproductive System in Women Living In the Aral Sea Region. *Open Access Macedonian Journal of Medical Sciences*, 3(3), 474–477. <https://doi.org/10.3889/oamjms.2015.078>
- Turdybekova, Y. G., Kopobayeva, I. L., & Kultanov, B. Z. (2017). Comparative Assessment of Women’s Reproductive Health in the Areas Bordering With the Aral Sea Region. *Open Access Macedonian Journal of Medical Sciences*, 5(2), 261–265. <https://doi.org/10.3889/oamjms.2017.052>
- Turdybekova, Y. G., Kopobayeva, I. L., Kultanov, B. Zh., Yesimova, R. Zh., & Fedotovskikh, G. V. (2018). Morphology of the Ovaries in Condition of Inhalation Intoxication with Dust-Saline Aerosols of the Aral Sea in Female White Rats. *Open Access Macedonian Journal of Medical Sciences*, 6(6), 997–1002. <https://doi.org/10.3889/oamjms.2018.240>
- Ukhov, Y. I., & Astrakhantsev, A. F. (1983). Morphometric methods in assessing the functional state of the testes. *Archive of Anatomy of Histology and Embryology*, 84(3), 66–72.
- Wahler, T. A., & Dietrichs, E. S. (2017). The vanishing Aral Sea: health consequences of an environmental disaster. *Tidsskrift for Den Norske Lægeforening*, 137(18), 1–9. <https://doi.org/10.4045/tidsskr.17.0597>
- Watanabe, N., & Oonuki, Y. (1999). Inhalation of diesel engine exhaust affects spermatogenesis in growing male rats. *Environmental Health Perspectives*, 107(7), 539–544. <https://doi.org/10.1289/ehp.99107539>
- Zhang, X., Zuo, Y., Zhang, J., Zhang, D., Naeem, M., Chang, Y., & Shi, Z. (2023). Sevoflurane inhibited reproductive function in male mice by reducing oxidative phosphorylation through inducing iron deficiency. *Frontiers in Cell and Developmental Biology*, 11, 1184632. <https://doi.org/10.3389/fcell.2023.1184632>