

Studies on Wound Healing and Antiulcer Activities of Extract of Aerial Parts of *Phyllanthus niruri* L. (Euphorbiaceae)

¹C.O. Okoli, ¹A.C. Ezike, ¹P.A. Akah, ²S.O. Udegbonam, ¹T.C. Okoye,
¹T.P. Mbanu and ¹E. Ugwu

¹Department of Pharmacology and Toxicology, Faculty of Pharmaceutical Sciences,
University of Nigeria, Nsukka 410001, Enugu State, Nigeria

²Department of Veterinary Surgery, Faculty of Veterinary Medicine,
University of Nigeria, Nsukka 410001, Enugu State, Nigeria

Abstract: Problem statement: *Phyllanthus niruri* is widely used in many parts of the world to manage a wide range of diseases. As part of efforts to elucidate its pharmacological activities and hence medicinal potential, we studied the wound healing and antiulcer properties of extract of the aerial parts using experimentally-created wounds and ulcers in rodents. **Approach:** Wound healing effect was assessed using excision and dead space wound models while antiulcer activity was evaluated using indomethacin-, ethanol acid- and cold-restraint stress-induced ulcer models. **Results:** The extract (5,10%) significantly ($p < 0.05$) reduced the wound diameter producing 90.9 and 93.7% wound contraction respectively on day 18 post wounding. It also reduced epithelialization time of excised wounds and increased the rate of wound closure, with WC_{50} of 8.7%. The extract (400 mg kg^{-1}) also significantly ($p < 0.05$) increased the weight of granuloma tissue. In antiulcer studies, the extract significantly ($p < 0.05$) inhibited the development of ulcers induced by indomethacin and moderately inhibited ethanol acid-induced ulcer. It was, however, devoid of any such effect in cold-restraint stress-induced lesions at the doses used. Phytochemical analysis of the extract revealed the presence of alkaloids, saponins, tannins, flavonoids, reducing sugar, carbohydrates and glycosides. **Conclusion:** These findings indicate that constituents of aerial parts of *P. niruri* possess wound healing and antiulcer properties.

Key words: Wound healing, antiulcer, *Phyllanthus niruri*

INTRODUCTION

Phyllanthus niruri L. (Euphorbiaceae) is an annual and field weed widespread in temperate and tropical climates^[1]. The morphology of the plant has been described^[2]. It is popularly used in Asia, Africa and South America^[3] as a stomachic, aperitive, antispasmodic, anti-hepatotoxic, antiviral, antibacterial, laxative, diuretic, carminative, in the management of diabetes, constipation, fever including malaria, jaundice, hepatitis B, dysentery, gonorrhoea, syphilis, tuberculosis, cough, influenza, diarrhoea, vaginitis, tumors, kidney stones^[4-9]. Studies on extracts from various parts of the plant have revealed the antioxidant^[10] and nitric oxide scavenging^[11], antimalarial (antiplasmodial)^[12-17], antihyperuricemic^[18], analgesic^[19,20], diuretic,

hypotensive, hypoglycemic^[21], hepatoprotective^[4,22-27], hepatocurative^[10], hypolipemic^[28], nematicidal^[29], platelet aggregation inhibitory^[30], nephrolithiatic^[31], HIV-1 reverse transcriptase inhibitory^[23], HIV replication inhibitory^[33], HIV/RRE binding inhibitory^[34], urolithiatic^[35-40] and vasorelaxant^[1] activities.

Several phytochemical constituents of this plant have been isolated and some were shown to be pharmacologically active. These include the alkaloids-4-methoxy-securinine (Phyllanthine) and 4-methoxy-nor-securinine^[41], arabinogalactan which stimulates superoxide anion production^[3,42], ellagic acid, brevifolin carboxylic acid and ethyl brevifolin carboxylate with aldose reductase inhibitory effect^[43], 1-O-galloyl-6-O-luteoyl- α -D-glucose with anti-babesial and antiplasmodial activities, beta-glucogallin,

Corresponding Author: A.C. Ezike, Department of Pharmacology and Toxicology, Faculty of Pharmaceutical Sciences, University of Nigeria, Nsukka 410001, Enugu State, Nigeria Tel: 2340852820538

quercetin 3-O-beta-d-glucopyranosyl-(2-1)-O-beta-d-xylopyranoside, beta sitosterol, gallic acid^[16], the lignans- phyllanthin, hypophyllanthin, phylltetralin with antihyperuricemic^[18] and antihepatotoxic effects^[4], cubebin dimethyl ether, urinatetralin^[44], niranthin^[45], methyl brevifolincarboxylate with vasorelaxant^[11] and platelet aggregation inhibitory^[30] effects, niruriside with HIV/RRE binding inhibitory effect^[34], the prenylated flavanones- 8-(3-Methyl-but-2-enyl)-2-phenylchroman-4-one and 2-(4-hydroxyphenyl)-8-(3-methyl-but-2-enyl)-chroman-4-one with nematocidal activity^[29], triacontanal and tricontanol with antihepatotoxic effect^[4] and xylans^[3].

In continuation of efforts to elucidate the pharmacological activities and hence medicinal potential of this plant, we studied the wound healing and antiulcer properties of extract of the aerial parts using experimentally created wounds and ulcers in rodents.

MATERIALS AND METHODS

Animals: Adult albino rats (150-200 g) of either sex obtained from the Department of Pharmacology and Toxicology, University of Nigeria Nsukka were used. The animals were housed in metal cages and maintained on standard pelleted rodent diet and water *ad libitum*. All animal experiments were in compliance with the National Institute of Health Guide for Care and Use of Laboratory Animals (Pub No. 85-23, revised 1985).

Drugs: Neomycin-bacitracin powder (Cicatr^(R)).

Reagents: Chloroform, methanol, dimethylsulfoxide (DMSO), ethanol.

Preparation and extraction of plant material: Fresh whole *P. niruri* plants were collected from Orba, Enugu State in May 2008 and authenticated by Mr. Alfred Ozioko of the International Centre for Ethnomedicine and Drug Development (InterCEDD) Nsukka, Nigeria. The plants were thoroughly cleaned and the aerial parts cut into smaller pieces, sun-dried for 7 days and milled to coarse powder using a mechanical grinder. The powdered plant material (2 kg) was extracted with methanol by continuous extraction in a soxhlet. Concentration of the extract in a rotary evaporator under reduced pressure afforded 140.6 g of the methanol extract (ME; 7.03% w/w). Phytochemical analysis for identification of constituents using conventional methods^[46,47] gave positive reactions for alkaloids, saponins, carbohydrates, reducing sugar,

flavonoids, steroids, terpenoids, tannins, resins and glycosides.

Wound healing activity studies: The effect of ME on wound healing was studied in rodents using experimentally-created excision and dead space wounds.

Excision wound: Animals randomly placed into four groups (I-IV; n = 6) were anaesthetized with chloroform and excision wounds (2.5 cm diameter) created on the depilated dorsal thoracic region^[48]. Groups I and II received ME (5 or 10%) ointment while III and IV were treated with neomycin-bacitracin (5%) or vehicle (ointment base) respectively. The ointments were topically applied once daily from day 1, after wound creation and continued until the wound healed. The wound diameter was measured on alternate days and the epithelialization period recorded at the end of the study. Wound contraction (%) was calculated using the relation:

$$\text{Wound contraction (\%)} = [(W_{D0} - W_{Dt}) / W_{D0}] \times 100$$

Where:

W_{D0} = The wound diameter on day zero

W_{Dt} = The wound diameter on day t

The time taken for 50% of wound closure (WC_{50}) was read off a plot of wound closure (%) against time (days).

Dead space wound: Dead space wounds were created by making a pouch through a small cut and implanting sterile cotton pellets (50 mg each) on either side of the axilla on the ventral surface of each rat. The animals were randomly divided into three groups (n = 6). Groups I and II received 200 or 400 mg kg^{-1} of ME suspended in DMSO (10%) respectively. Group III served as control and received the vehicle. Extract administration was done orally once a day from day 0-9. On day 10, the animals were sacrificed by overdose of chloroform anaesthesia and the pellets carefully removed and dried in an oven at 60°C to a constant weight and the weight recorded. The level of increase (%) in the weight of granuloma tissue formed was calculated relative to the control.

Antiulcer activity studies: The ulcer-healing or protective effect of the extract was studied in rodents using ulcers induced by different ulcerogens.

Indomethacin-induced ulcers: Animals were fasted for 18 h but allowed access to water only prior to the

experiment and divided into 4 groups (n = 6). Groups I and II received 200 or 400 mg kg⁻¹ of ME, while III and IV received cimetidine (32 mg kg⁻¹) or the vehicle (10% v/v DMSO) respectively. Thirty minutes after oral administration of extract, ulcer was induced by oral administration of indomethacin (20 mg kg⁻¹). After 7 h, the animals were scarified and the abdomen opened. The stomach was isolated and opened along the greater curvature and rinsed under a stream of water. Lesions on the gastric mucosa were observed with a hand lens (x10)^[49] and scored 0-4 using an arbitrary scale where 0 = no lesions; 0.5 = hyperemia; 1 = one or two lesions; 2 = severe lesions; 3 = very severe lesions and 4 = mucosa full of lesions^[50].

Ethanol-acid induced ulcers: Animals were fasted, grouped and treated as above. Thirty minutes after oral administration of ME, ulcer was induced with oral administration of ethanol-acid (25 mL kg⁻¹ of 0.3 M HCl in 60% ethanol)^[51]. One hour later, the animals were sacrificed and their stomachs removed and cut along the greater curvature. The open stomach was rinsed in a stream of water and the lesions on the gastric mucosa observed and scored as described above.

Cold-restraint stress-induced ulcer: Acute, gastric lesions were induced by stress according to a modified method of Nagura and Bacchi^[52,53]. Animals were fasted for 18 h, grouped and treated as above. Thirty minutes after oral administration of ME, ulcer was induced by immobilizing the animals in cylindrical cages vertically placed in bowls containing water to the level of the xiphoid process. The bowls were kept in a refrigerator maintained at 19°C. After 17 h, the animals were sacrificed by overdose of chloroform anaesthesia and their stomachs removed and opened along the greater curvature. The stomach was rinsed in a stream of water and the ulcer lesions observed and scored as described above.

Statistical analysis: The data obtained was analyzed using One-way analysis of variance (ANOVA) and further subjected to LSD post hoc test for multiple comparisons. The results were presented as Mean ± SEM. Differences between means was accepted significant at p<0.05.

RESULTS

Effect of ME on excision wound: Topical application of ME caused a significant (p<0.05) concentration-related reduction in wound diameter (Table 1). The ME also significantly (p<0.05) reduced the epithelialization period of excision wounds (Table 2). On day 18, ME-treated rats showed 93.7% wound contraction compared to control rats (84.2%). The WC₅₀ values showed that ME (10%) produced a better wound closure rate (8.7 days) than cicatrin (9.0 days) (Fig. 1).

Effect of ME on dead space wound: In the dead space wound model, oral administration of ME caused a significant (p<0.05) and dose-related increase in the weight of granuloma tissue (Table 3).

Effect of ME on indomethacin-induced ulcer: The ME significantly (p<0.05) inhibited the development of indomethacin-induced ulcer in a dose-related manner. The effect of the higher dose was comparable to that of cimetidine (Table 4).

Effect of ME on ethanol acid-induced ulcer: The ME (400 mg kg⁻¹) moderately inhibited the development of ulcers induced by ethanol acid (Table 4).

Effect of ME on cold-restraint stress-induced ulcer: Pretreatment with ME did not prevent the development of ulcers induced by cold restraint stress (Table 4).

Table 1: Effect of extract on diameter of excision wounds in rats

Treatment	Conc. (%)	Wound diameter (mm)									
		Day 0	Day 2	Day 4	Day 6	Day 8	Day 10	Day 12	Day 14	Day 16	Day 18
ME	5	23.83±0.74	23.0±0.84 (3.43)	21.67±0.46 (9.06)	19.83±0.28 (16.79)	17.33±1.01 (27.28)	7.17±0.21* (69.91)	5.33±0.11* (77.63)	4.00±0.32* (82.21)	2.83±0.11* (88.12)	2.17±0.11 (90.89)
	10	23.67±0.42	22.83±0.53 (3.55)	21.00±0.95 (11.28)	18.33±0.84 (22.56)	14.00±1.26 (40.85)	7.50±0.63 (68.31)	5.50±0.63* (76.76)	3.67±0.05* (84.5)	2.00±1.26* (91.55)	1.50±0.95* (93.66)
Cicatrin	5	23.50±0.66	22.83±0.56 (2.85)	20.50±0.95 (12.77)	18.33±0.64 (22)	14.50±0.79 (38.3)	9.17±0.38 (60.98)	6.50±0.48* (72.34)	4.83±0.46 (79.45)	3.67±0.46 (84.38)	2.17±0.74 (90.77)
Control	-	24.17±0.53	23.67±0.56 (2.06)	22.33±0.82 (7.61)	19.83±0.56 (17.96)	16.00±0.48 (33.80)	11.67±1.53 (51.72)	8.50±0.48 (64.83)	6.83±0.82 (71.74)	5.33±0.56 (77.95)	3.83±0.56 (84.15)

n = 6; *: p<0.05 compared to control (ANOVA; LSD post hoc); ME: Methanol Extract; Values of wound diameter shown are Mean ± SEM; Values in parenthesis represent wound closure (%) calculated relative to the wound diameter on day 0

Table 2: Effect of extract on epithelialization period of excision wounds in rats

Treatment	Conc. (%)	Epithelialization period (Days)	Reduction (%)
ME	5	20.0±0.0	14.27
	10	17.0±1.26*	27.13
Cicatrin	5	19.3±0.42*	17.15
Control	-	23.3±0.84	-

n = 6; *: p<0.05 compared to control (ANOVA; LSD post hoc); ME: Methanol Extract; Values of epithelialisation period shown are Mean ± SEM; Reduction (%) was calculated relative to the control

Table 3: Effect of extract on granulation tissue formation in rats

Extract	Dose (mg kg ⁻¹)	Weight of granuloma tissue (mg)	Increase in granuloma tissue (%)
ME	200	211.83±6.03	10.43
	400	386.17±28.96*	101.70
Control	-	191.83±18.71	-

n = 6; *: p<0.05 compared to Control (ANOVA; LSD post hoc); ME: Methanol Extract; Values of granuloma tissue weight are Mean ± SEM; Increase in granuloma tissue was calculated relative to the control

Table 4: Effect of extract on ulcers induced by various agents in rats

Treatment	Dose (mg kg ⁻¹)	Ulcer scores		
		Indomethacin ulcer	Ethanol-acid ulcer	Cold restraint stress ulcer
ME	200	2.50±0.66 (16.67)	0.67±0.11 (NI)	2.83±0.74 (NI)
	400	0.83±0.11* (72.33)	0.50±0.0 (25.37)	2.67±0.42 (NI)
Cimetidine	32	0.67±0.11* (77.67)	0.17±0.11* (70.15)	2.33±0.21 (NI)
		3.00±0.37	0.67±0.11	2.33±0.56

n = 6; *: p<0.05 compared to Control (ANOVA; LSD post hoc); ME: Methanol Extract; Ulcer scores shown are Mean ± SEM; The ulcer lesions were scored 0-4 where 0 = no lesions; 0.5 = hyperemia; 1 = one or two lesions; 2 = severe lesions; 3 = very severe lesions and 4 = mucosa full of lesions; Values in parenthesis represent ulcer inhibition (%) calculated relative to control

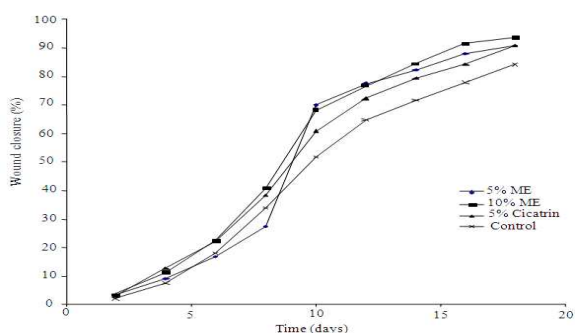


Fig.1: Effect of extract on wound closure

DISCUSSION

Wounds occur when the continuity of the skin or mucous membrane is broken^[54]. On the other hand, peptic ulcers, are benign lesions of gastric or duodenal

mucosa which result from a shift in the balance between the aggressive (acid, pepsin, *H. pylori*) and protective (gastric mucus and bicarbonate secretion, prostaglandins) mechanisms. While wounds occur under acute conditions and are healed through a natural process that may be prolonged without treatment, peptic ulcers are amplified and sustained by their pathophysiological mechanisms. Whatever is the basic amplification mechanism of the disease process; treatment with wound-healing or anti-ulcer agents respectively stimulates or accelerates healing.

Experimental assessment of the wound healing and antiulcer activities of *P. niruri* extract showed increased rate of wound contraction and epithelialization, increased granuloma tissue formation and protection of the gastric mucosa from ulcerogenic effects of indomethacin and ethanol-acid in treated animals. Chronic topical application of the extract on excision wounds accelerated wound contraction and reduced epithelialization period in rats. Wound healing involves regeneration of specialized cells by proliferation of surviving cells and connective tissue response characterized by the formation of granulation tissue^[55]. It is also characterized by haemostasis, re-epithelialization and remodeling of the extracellular matrix. Epithelialization, which is the process of epithelial renewal after injury, involves the proliferation and migration of epithelial cells towards the centre of the wound while wound contraction is largely due to the action of myofibroblasts^[56,57]. Thus, the effect of the extract on wound contraction and epithelialization suggest it may enhance epithelial cells migration and proliferation, as well as the formation, migration and action of myofibroblasts. On chronic oral administration, the extract enhanced granuloma tissue formation in dead space wounds. Granuloma tissue formed on an inert foreign body in a dead space comprises an accumulation of modified macrophages^[55] and histological giant cells and undifferentiated connective tissue consisting largely of collagen^[55,57,58]. Increase in granuloma tissue, in dead space wound, is associated with enhanced collagen maturation and increased protein content as well as angiogenesis^[59-61] in the wound. These processes are indicators of new tissues generation and suggest that the extract may stimulate mechanisms associated with tissue regeneration. Closely related to this is the effect of growth factors secreted by macrophages on wounds. Macrophages secrete peptide growth factors that exert pro-healing effect by stimulating regeneration, fibroblast proliferation and activation and angiogenesis^[55]. It is, therefore, likely that in addition to enhancing wound contraction and epithelialization, the

extract may also stimulate processes associated with tissue regeneration.

In antiulcer studies, treatment with the extract protected rats from ulcers induced by indomethacin and ethanol-acid. These agents induce ulcers by different but related mechanisms that basically undermine gastric mucosal integrity and hence cytoprotection. Gastric mucosal damage caused by indomethacin and related non-steroidal anti-inflammatory drugs result from the inhibition of prostaglandins synthesis via the arachidonic pathway^[62,63]. Prostaglandins serve protective functions in the stomach by maintaining gastric microcirculation^[62,64] and causing gastric secretion of bicarbonate^[65] and mucus^[66]. Thus, the effect of the extract in this model suggests it may possess cytoprotective action probably by enhancing prostaglandins synthesis. The extract also mildly protected the gastric mucosa against ethanol-acid challenge. Ethanol-induced gastric mucosal lesions, predominant in the glandular part of the stomach, are caused by the direct toxic action of ethanol, reduction of the secretion of bicarbonate and depletion of gastric wall mucus^[67,68]. Ethanol also reduces endogenous glutathione and prostaglandin levels, increases the release of histamine and influx of calcium ions^[69] and stimulates the synthesis of leukotriene C₄ (LTC₄)^[70-72] and oxygen free radicals^[73] thus causing increased lipid peroxidation which damages cells and cell membranes^[74]. Agents that enhance mucosal defensive factors inhibit ethanol-induced gastric mucosal lesions^[75]. This is consistent with our earlier suggestion that the extract may owe its antiulcer effect to cytoprotection probably due to enhancement of prostaglandins synthesis. Although the precise mechanism of cytoprotection remains to be elucidated, the level of protection offered by the extract against indomethacin ulcers directly suggests it may enhance prostaglandins synthesis. This may be the reason for its ineffectiveness in protecting rats against cold-restraint-stress ulcers where factors other than suppression of prostaglandin synthesis play major causative roles. Cold restraint ulcers are caused by factors such as increase in gastric motility and gastric acid secretion, decrease in pH^[76], vagal overactivity, mast cell degranulation, decrease in mucosal blood flow, gastric mucus and prostaglandins synthesis as well as generation of free radicals^[77-81]. The extent of interaction of the extract with these mechanisms is not known, although the antioxidant^[10] and radical scavenging^[11] effects of this plant have been reported. Besides the likelihood of prostaglandin synthesis enhancement, it is unlikely that the extract interferes with any of the major processes responsible for ulcer

induction in this model. As such, extract of aerial parts of this plant may not be effective in all cases of ulcer.

CONCLUSION

In conclusion, the results of this study indicate that aerial parts of *P. niruri* exhibit wound healing and antiulcer activities by accelerating wound closure and epithelialization and enhancing mucosal protection possibly by mobilization of endogenous prostaglandins. Although the extract may be effective in accelerating the healing of wounds, it may not be effective in all cases of ulcer.

REFERENCES

1. Iizuka, T., H. Moriyama and M. Nagai, 2006. Vasorelaxant effects of methyl brevivolinocarboxylate from the leaves of *Phyllanthus niruri*. Biol. Pharm. Bull., 29: 177-179. <http://www.ncbi.nlm.nih.gov/pubmed/16394535>
2. Bagalkotkar, G., S.R. Sagineedu, M.S. Saad and J. Stanslas, 2006. Phytochemicals from *Phyllanthus niruri* Linn. and their pharmacological properties: A review. J. Pharm. Pharmacol., 58: 1559-1570. DOI: 10.1211/jpp.58.12.0001
3. Mellinger, C.G., E.R. Carbonero, G.R. Noletto, T.R. Cipriani and M.B. Oliveira *et al.*, 2005. Chemical and biological properties of an arabinogalactan from *Phyllanthus niruri*. J. Nat. Prod., 68: 1479-83. <http://www.ncbi.nlm.nih.gov/pubmed/16252911>
4. Syamasundar, K.V., 1985. Antihepatoprotective principles of *Phyllanthus niruri* herbs. J. Ethnopharmacol., 14: 41-44. <http://www.ncbi.nlm.nih.gov/pubmed/4087921>
5. Olive-Bever, B., 1986. Medicinal Plants in Tropical West Africa. Cambridge University Press, Cambridge, ISBN: 052126815X, pp: 375.
6. Chopra, R.N., S.L. Nayar and I.C. Chopra, 1986. Glossary of Indian Medicinal Plants. CSIR., Catholic Press, New Delhi, Ranchi, India. ISBN: 8172361262.
7. Unander, D.W., G.L. Webster and B.S. Blumberg, 1995. Usage and bioassays in *Phyllanthus* (Euphorbiaceae). IV. Clustering of antiviral uses and other effects. J. Ethnopharmacol., 45: 1-18. <http://www.ncbi.nlm.nih.gov/pubmed/7739222>.
8. Paranjape, P., 2001. Indian Medicinal Plants: Forgotten Healers. Chaukhamba Sanskrit Pratisthan, Delhi, pp: 315. <http://books.google.com.pk/books?id=4w1GQAACA AJ&dq=Indian+Medicinal+Plants:+Forgotten+Healers>

9. Lin, T.J., C.C. Su, C.K. Lan, D.D. Jiang, J.L. Tsai and M.S. Tsai, 2003. Acute poisonings with *Breynia officinalis*-an outbreak of hepatotoxicity. *J. Toxicol. Clin. Toxicol.*, 41: 591-594. <http://www.ncbi.nlm.nih.gov/pubmed/14514003>
10. Tasaduq, S.A., K. Singh, S. Sethi, S.C. Sharma, K.L. Bedi, J. Singh, B.S. Jaggi and R.K. Johri, 2003. Hepatocurative and antioxidant profile of HP-1, a polyherbal phytomedicine. *Hum. Exp. Toxicol.*, 22: 639-45. <http://www.ncbi.nlm.nih.gov/pubmed/14992325>
11. Jagetia, G.C. and M.S. Baliga, 2004. The evaluation of nitric oxide scavenging activity of certain Indian medicinal plants *in vitro*: A preliminary study. *J. Med. Food*, 7: 343-8. <http://www.ncbi.nlm.nih.gov/pubmed/15383230>
12. Tona, L., N.P. Ngimbi, M. Tsakala, K. Mesia and K. Cimanga *et al.*, 1999. Antimalarial activity of 20 crude extracts from nine African medicinal plants used in Kinshasa, Congo. *J. Ethnopharmacol.*, 68: 193-203. <http://www.ncbi.nlm.nih.gov/pubmed/10624878>
13. Tona, L., K. Mesia, N.P. Ngimbi, B. Chrimwami and A. Okond'Ahoka *et al.*, 2001. *In vivo* antimalarial activity of *Cassia occidentalis*, *Morinda morindoides* and *Phyllanthus niruri*. *Ann. Trop. Med. Parasitol.*, 95: 47-57. <http://www.ncbi.nlm.nih.gov/pubmed/11235553>
14. Cimanga, R.K., L. Tona, N. Luyindula, K. Mesia and M. Lusakibanza *et al.*, 2004. *In vitro* antiplasmodial activity of callus culture extracts and fractions from fresh apical stems of *Phyllanthus niruri* L. (Euphorbiaceae): Part 2. *J. Ethnopharmacol.*, 95: 399-404. <http://www.ncbi.nlm.nih.gov/pubmed/15507366>
15. Tona, L., R.K., Cimanga, K. Mesia and C.T. Musuamba *et al.*, 2004. *In vitro* antiplasmodial activity of extracts and fractions from seven medicinal plants used in the Democratic Republic of Congo. *J. Ethnopharmacol.*, 93: 27-32. <http://www.ncbi.nlm.nih.gov/pubmed/15182900>
16. Subeki, S., H. Matsuura, K. Takahashi, M. Yamasaki and O. Yamato *et al.*, 2005. Anti-babesial and antiplasmodial compounds from *Phyllanthus niruri*. *J. Nat. Prod.*, 68: 537-9. <http://www.ncbi.nlm.nih.gov/pubmed/15844943>
17. Mustofa, E.N., Sholikhah and S. Wahyuono, 2007. *In vitro* and *in vivo* antiplasmodial activity and cytotoxicity of extracts of *Phyllanthus niruri* L. herbs traditionally used to treat malaria in Indonesia. *Southeast Asian J. Trop. Med. Public Health*, 38:609-15. <http://www.ncbi.nlm.nih.gov/pubmed/17882995>
18. Murugaiyah, V., K.L. Chan, 2006. Antihyperuricemic lignans from the leaves of *Phyllanthus niruri*. *Planta Med.*, 72: 1262-7. <http://www.ncbi.nlm.nih.gov/pubmed/16953466>
19. Santos, A.R., V.C. Filho, R.A. Yunes and J.B. Calixto, 1995. Analysis of the mechanisms underlying the antinociceptive effect of the extracts of plants from the genus *Phyllanthus*. *Gen. Pharmacol.*, 26: 1499-1506. <http://www.ncbi.nlm.nih.gov/pubmed/8690236>
20. Santos, A.R., V.C. Filho, R. Niero, A.M. Viana and F.N. Moreno *et al.*, 1994. Analgesic effects of callus culture extracts from selected species of *Phyllanthus* in mice. *J. Pharm. Pharmacol.*, 46: 755-759. <http://www.ncbi.nlm.nih.gov/pubmed/7837046>
21. Ramakrishnan, P.N., R. Murugesan, S. Palanichamy, 1982. Oral hypoglycaemic effect of *Phyllanthus niruri* leaves. *Indian J. Pharm. Sci.*, 44: 10-12. <http://indianmedicine.eldoc.ub.rug.nl/root/R/95931/?pFullItemRecord=ON>
22. Chatterjee, M. and P.C. Sil, 2006. Hepatoprotective effect of aqueous extract of *Phyllanthus niruri* on nimesulide-induced oxidative stress *in vivo*. *Indian J. Biochem. Biophys.*, 43: 299-305. <http://www.ncbi.nlm.nih.gov/pubmed/17133737>
23. Bhattacharjee, R. and P.C. Sil, 2006. The Protein Fraction of *Phyllanthus niruri* plays a protective role against acetaminophen induced hepatic disorder via its antioxidant properties. *Phyther. Res.*, 20: 595-601. <http://www.ncbi.nlm.nih.gov/pubmed/16718736>
24. Chatterjee, M., K. Sarkar and P.C. Sil, 2006. Herbal (*Phyllanthus niruri*) protein isolate protects liver from nimesulide induced oxidative stress. *Pathophysiology*, 13: 95-102. <http://www.ncbi.nlm.nih.gov/pubmed/16542828>
25. Sarkar, M.K. and P.C. Sil, 2007. Hepatocytes are protected by herb *Phyllanthus niruri* protein isolate against thioacetamide toxicity. *Pathophysiology*, 14: 113-20. DOI: 10.1016/j.pathophys.2007.08.001
26. Bhattacharjee, R. and P.C. Sil, 2007. Protein isolate from the herb, *Phyllanthus niruri* L. (Euphorbiaceae), plays hepatoprotective role against carbon tetrachloride induced liver damage via its antioxidant properties. *Food Chem. Toxicol.*, 45: 817-26. <http://www.ncbi.nlm.nih.gov/pubmed/17175085>
27. Manjrekar, A.P., V. Jisha, P.P. Bag, B. Adhikary, M.M. Pai, A. Hegde and M. Nandini, 2008. Effect of *Phyllanthus niruri* Linn. treatment on liver, kidney and testes in CCl₄ induced hepatotoxic rats. *Indian J. Exp. Biol.*, 46: 514-20. <http://www.ncbi.nlm.nih.gov/pubmed/18807755>

28. Khanna, A.K., F. Rizvi and R. Chander, 2002. Lipid lowering activity of *Phyllanthus niruri* in hyperlipemic rats. J. Ethnopharmacol., 82: 19-22. <http://www.ncbi.nlm.nih.gov/pubmed/12169400>
29. Shakil, N.A., J. Pankaj, R.K. Kumar, Pandey and D.B. Saxena, 2008. Nematicidal prenylated flavanones from *Phyllanthus niruri*. Phytochemistry, 69: 759-64. DOI: 10.1016/j.phytochem.2007.08.024
30. Iizuka, T., M. Nagai, A. Taniguchi, H. Moriyama and K. Hoshi, 2007. Inhibitory effects of methyl brevifolincarboxylate isolated from *Phyllanthus niruri* L. on platelet aggregation. Biol. Pharm. Bull., 30: 382-384. <http://www.ncbi.nlm.nih.gov/pubmed/17268086>
31. Kieley, S., R. Dwivedi and M. Monga, 2008. Ayurvedic medicine and renal calculi. J. Endourol., 22: 1613-1616. <http://www.ncbi.nlm.nih.gov/pubmed/18620498>
32. Ogata, T., H. Higuchi, S. Mochida, H. Matsumoto, A. Kato, T. Endo, A. Kaji and H. Kaji, 1992. HIV-1 reverse transcriptase inhibitor from *Phyllanthus niruri*. AIDS Res. Hum. Retrovir., 8: 1937-44. <http://www.ncbi.nlm.nih.gov/pubmed/1283310>
33. Naik, A.D. and A.R. Juvekar, 2003. Effects of alkaloidal extract of *Phyllanthus niruri* on HIV replication. Indian J. Med. Sci., 57: 387-393. <http://www.ncbi.nlm.nih.gov/pubmed/14515028?dopt=Abstract>
34. Qian-Cutrone, J., S. Huang, J. Trimble, H. Li, P.F. Lin, M. Alam, S.E. Klohr and K.F. Kadow, 1996. Niruriside, a new HIV REV/RRE binding inhibitor from *Phyllanthus niruri*. J Nat. Prod., 59: 196-199. <http://www.ncbi.nlm.nih.gov/pubmed/8991954>
35. Campos, A.H. and N. Schor, 1999. *Phyllanthus niruri* inhibits calcium oxalate endocytosis by renal tubular cells: Its role in urolithiasis. Nephron, 81: 393-397. <http://www.ncbi.nlm.nih.gov/pubmed/10095174>
36. Freitas, A.M., N. Schor and M.A. Boim, 2002. The effect of *Phyllanthus niruri* on urinary inhibitors of calcium oxalate crystallization and other factors associated with renal stone formation. BJU. Int., 89: 829-34. <http://www.ncbi.nlm.nih.gov/pubmed/12010223>
37. Barros, M.E., N. Schor and M.A. Boim, 2003. Effects of an aqueous extract from *Phyllanthus niruri* on calcium oxalate crystallization *in vitro*. Urol. Res., 30: 374-379. <http://www.ncbi.nlm.nih.gov/pubmed/12599017>
38. Nishiura, J.L., A.H. Campos, M.A. Boim, I.P. Heilberg and N. Schor, 2004. *Phyllanthus niruri* normalizes elevated urinary calcium levels in Calcium Stone Forming (CSF) patients. Urol. Res., 32: 362-366. <http://www.ncbi.nlm.nih.gov/pubmed/15221244>
39. Micali, S., M.C. Sighinolfi, A. Celia, S. De Stefani, M. Grande, A.F. Cicero and G. Bianchi, 2006. Can *Phyllanthus niruri* affect the efficacy of extracorporeal shock wave lithotripsy for renal stones? A randomized, prospective, long-term study. J. Urol., 176: 1020-1022. <http://www.ncbi.nlm.nih.gov/pubmed/16890682>
40. Barros, M.E., R. Lima, L.P. Mercuri, J.R. Matos, N. Schor and M.A. Boim, 2006. Effect of extract of *Phyllanthus niruri* on crystal deposition in experimental urolithiasis, Urol. Res., 34: 351-357. <http://www.ncbi.nlm.nih.gov/pubmed/16896689>
41. Mulchandani, N.B. and S.A. Hassarajani, 1984. 4-Methoxy-nor-Securinine, a New Alkaloid from *Phyllanthus niruri*. Planta Med., 50: 104-105. <http://www.ncbi.nlm.nih.gov/pubmed/17340265>
42. Mellinger, C.G., T.R. Cipriani, G.R. Noletto, E.R. Carbonero and M.B. Oliveira *et al.*, 2008. Chemical and immunological modifications of an arabinogalactan present in tea preparations of *Phyllanthus niruri* after treatment with gastric fluid. Int. J. Biol. Macromol., 43: 115-120. <http://www.ncbi.nlm.nih.gov/pubmed/18501421>
43. Shimizu M, S. Horie, S. Terashima, H. Ueno and T. Hayashi *et al.*, 1989. Studies on aldose reductase inhibitors from natural products. II. Active components of a Paraguayan crude drug "Paraparai mí," *Phyllanthus niruri*. Chem. Pharm. Bull. (Tokyo), 37: 2531-2532. <http://www.ncbi.nlm.nih.gov/pubmed/2514047>
44. Elfahmi, S. Batterman, A. Koulman, T. Hackl and R. Bos *et al.*, 2006. Lignans from cell suspension cultures of *Phyllanthus niruri*, an Indonesian medicinal plant. J. Nat. Prod., 69: 55-58. <http://www.ncbi.nlm.nih.gov/pubmed/16441068>
45. Murugaiyah, V and K.L. Chan, 2007. Determination of four lignans in *Phyllanthus niruri* L. by a simple high-performance liquid chromatography method with fluorescence detection. J. Chromatogr. A., 1154: 198-204. <http://www.ncbi.nlm.nih.gov/pubmed/17418855>
46. Harborne, J.B.C., 1973. Phytochemical Methods. Chapman and Hall, London, ISBN: 0412105403 pp: 278
47. Trease, G.E. and W.C. Evans, 1983. Drugs of Biological Origin. In: Pharmacognosy. 12th Edn., Balliere Tindall, United Kingdom, ISBN: 0702010073, pp: 821.
48. Morton, J.J.P. and M.H. Malone, 1972. Evaluation of vulnerary activity by an open procedure in rats. Arch. Int. Pharmacodyn., 117-126. <http://www.ncbi.nlm.nih.gov/pubmed/5059357>

49. Aguwa, C.N. and G.C. Mittal, 1981. Study of antiulcer activity of aqueous extract of leaves of *Pyrenacantha standtii* (Family Icacinaceae) using various models of experimental gastric ulcer in rats. Eur. J. Pharmacol., 74: 215-219. <http://www.ncbi.nlm.nih.gov/pubmed/7327202>
50. Cashin, C.H., W. Dawson and E.A. Kitchen, 1979. The pharmacology of benoxaprofen (2-4-chlorophenyl-methyl-5-benzoxazole acetic acid) LRC.L3694, a new compound with anti-inflammatory activity apparently unrelated to inhibition of prostaglandin synthetase. J. Pharm. Pharmacol., 29: 330-336. <http://www.ncbi.nlm.nih.gov/pubmed/18568>
51. Mizui, T. and M. Douteuchi, 1983. Effect of polyamines on acidified ethanol induced gastric lesions in rats. Jap. J. Pharmacol., 33: 939-945. <http://www.ncbi.nlm.nih.gov/pubmed/6580476>
52. Nagura, M., 1972. Effect of psychotropic drugs on catecholamines in brain and adrenal medulla of rats under stress producing peptic ulcers. Jap. J. Pharmacol., 22: 545-549. <http://www.ncbi.nlm.nih.gov/pubmed/4539507>
53. Goulart, Y.C.F., V.R. Sela, S. Obici, J.V.C. Martins, F. Otobone, D.A. Cortez, E.A. Audi, 2005. Evaluation of gastric anti-ulcer activity in a hydroethanolic extract from *Kielmeyera coriacea*. Braz. Arch. of Biol. and Technol., 48: 211-216. <http://www.scielo.br/pdf/babt/v48n2/23760.pdf>
54. Ross, J.S. and J.W.K. Wilson, 1970. Foundation of Nursing and First Aid. 5th Edn., Churchill Livingstone, Edinburgh, ISBN: 0443007357, pp: 304.
55. Whaley, K. and A.D. Burt, 1996. Inflammation, Healing and Repair. In: Muir's Textbook of Pathology, MacSween, R.M.N. and K. Whaley (Eds.). 13th Edn., Arnold, London ISBN: 0340569573, pp: 112-165.
56. Cotran, R.S., V. Kumar, S.L. Robbins and F.J. Schoen, 1994. Inflammation and Repair. In: Robbins Pathologic Basis of Disease, 5th Edn, W.B. Saunders Company, Pennsylvania, ISBN: 0-7216-5032-5, pp: 51-92.
57. Mohan, H., 2005. Inflammation and Healing. In: Textbook of Pathology, 5th Edn., Jaypee Brothers, New Delhi, ISBN: 81-8061-368-2, pp: 133-179.
58. Bairy, K.L. and C.M. Rao, 2001. Wound healing profiles of *Ginkgo biloba*. J. Nat. Rem., 1/1: 25-27. www.jnronline.com/body_volume.1.html
59. Azad, S., 2002. Essentials of Surgery. Paras Medical Publications, Hyderabad, ISBN: 8181911180, pp: 1.
60. Swamy, K.H., V. Krishna, K. Shankarmurthy, A.B. Rahiman and K.L. Mankani *et al.*, 2007. Wound healing activity of embelin isolated from the ethanol extract of leaves of *Embelia ribes* Burm. J. Ethnopharmacol., 109: 529-534. DOI: 10.1016/j.jep.2006.09.003
61. Harish, B.G., V. Krishna, H.S. Kumar, K.B. Ahamed, R. Sharath and K.H. Swamy, 2008. Wound healing activity and docking of glycogen-synthase-kinase-3- β -protein with isolated triterpenoid lupeol in rats. Phytomedicine, 15: 763-767. DOI: 10.1016/j.phymed.2007.11.017
62. Vane, J.R., 1971. Inhibition of prostaglandin synthesis as a mechanism of action of aspirin-like drugs. Nat. N. Biol., 231: 232-235. <http://www.ncbi.nlm.nih.gov/pubmed/5284360>
63. Soll, A.H., W.M. Weinstein, J. Kurata and D. McCarthy, 1991. Non-steroidal anti-inflammatory drugs and peptic ulcer disease. Ann. Intern. Med., 114: 307-319. <http://www.ncbi.nlm.nih.gov/pubmed/1987878>
64. Ferreira, S.J. and J.R. Vane, 1974. New aspects of the mode of actions of NSAIDs. Ann. Rev. Pharmacol., 14: 57-70.
65. Garner, A., G. Flemstrom and J.R. Heylings, 1979. Effects of anti-inflammatory agents and prostaglandins on acid and bicarbonate secretions in the amphibian isolated gastric mucosa. Gastroenterology, 77: 451-457. <http://www.ncbi.nlm.nih.gov/pubmed/313351>
66. Menguy, R. and L. Desbaillets, 1967. Role of inhibition of gastric mucous secretion in the phenomenon of gastric mucosal injury by indomethacin. Am. J. Dig. Dis., 12: 862-866. <http://www.ncbi.nlm.nih.gov/pubmed/6039569>
67. Koo, M.W.L., C.W. Ogle and C.H. Cho, 1986. Effect of verapamil, carbenoxolone and N-acetylcysteine on gastric wall mucus and ulceration in stressed rats. Pharmacology, 32: 236-334. <http://www.ncbi.nlm.nih.gov/pubmed/3725888>
68. Marhuenda, E., M.J. Martin and C.A.D. La Lastra, 1993. Anti-ulcerogenic activity of aescine in different experimental models. Phytoter. Res., 7: 13-16. <http://cat.inist.fr/?aModele=afficheN&cpsidt=4556332>
69. Galvin, G.B. and S. Szabo, 1992. Experimental gastric mucosal injury: Laboratory models reveal mechanisms of pathogenesis and new therapeutic strategy. Federat. Am. Soc. Exp. Biol. J., 6: 825-831. <http://cat.inist.fr/?aModele=afficheN&cpsidt=11350134>
70. Dreyling, K.W., K. Lange, B.A. Peskar and B.M. Peskar, 1986. Release of leukotrienes by rat and human gastric mucosa and its pharmacological modification. Br. J. Pharmacol. Proc. Suppl., 88: 236. PMID: PMC1916919.

71. Peskar, B.M., K. Lange, U. Hoppe and B.A. Peskar, 1986. Ethanol stimulates formation of leukotriene C₄ in rat gastric mucosa. *Prostaglandins*, 31: 283-293. <http://www.ncbi.nlm.nih.gov/pubmed/3515429>
72. Cho, C.H., C.W. Ogle and E.L. Sevila, 1987. The protective effect of sulphasalazine against ethanol-induced gastric damage in rats. *Br. J. Pharmacol.*, 92: 31-37. <http://www.ncbi.nlm.nih.gov/pubmed/2889494>
73. Mizui, T. and M. Doteuchi, 1986. Lipid peroxidation a possible role in gastric damage induced by ethanol in rats. *Life Sci.*, 38: 2163-2167. <http://www.ncbi.nlm.nih.gov/pubmed/3458990>
74. Pihan, G., C. Regillo and S. Szabo, 1987. Free radicals and lipid peroxidation in ethanol-or aspirin-induced gastric mucosal injury. *Dig. Dis. Sci.*, 32: 1395-1401. <http://www.ncbi.nlm.nih.gov/pubmed/3691277>
75. Robert, A., J.E. Nezamis, C. Lancaster and A.J. Hanchar, 1979. Cytoprotection by prostaglandins in rats. Prevention of gastric necrosis produced by alcohol, HCl, NaOH, hypertonic NaCl and thermal injury. *Gastroenterology*, 77: 433-443. <http://www.cababstractsplus.org/abstracts/Abstract.aspx?AcNo=19791495041>
76. Murakami, M., S.K. Lam, M. Inada and T. Miyake, 1985. Pathophysiological and pathogenesis of acute gastric mucosal lesions after hypothermic-restraint stress in rats. *Gastroenterology*, 88: 660-665. <http://www.ncbi.nlm.nih.gov/pubmed/3967803>
77. Okubo, T., Y. Watanabe, T. Kidokoro, K. Ishihara and K. Hotta, 1986. Correlation of quantitative changes of gastric mucosal glycoproteins in restraint and water immersion stress in rats. *Jap. J. Gastroenterol.*, 83: 1111-1116. <http://www.ncbi.nlm.nih.gov/pubmed/3761679>
78. Hase, T. and B.J. Moss, 1973. Microvascular changes of gastric mucosa in development of stress ulcers in the rats. *Gastroenterology*, 65: 224-234. <http://www.ncbi.nlm.nih.gov/pubmed/4720026>
79. Cho, C.H., C.W. Ogle and S. Dai, 1976. Acute gastric ulcer formation in response to Electrical Vagal stimulation in rats. *Eur. J. Pharmacy.*, 35: 215-219. <http://www.ncbi.nlm.nih.gov/pubmed/1253823>
80. Garrick, T., S. Buack and P. Bass, 1986. Gastric motility is a major factor in cold restraint induced lesion formation in rats. *Am. J. Physiol.*, 250: G191-199. <http://www.ncbi.nlm.nih.gov/pubmed/3953798>
81. Rachchh, M.A. and S.M. Jain, 2008. Gastroprotective effect of *Benincasa hispida* fruit extract. *Ind. J. Pharmacol.* 40: 271-275. <http://indianmedicine.eldoc.ub.rug.nl/root/R2/312r/?pFullItemRecord=ON>