

Original Research Paper

Newcastle Disease Virus VII.2 First Record in Kazakhstan

¹Marina Kopochenya, ¹Belan Astemirov, ²Karina Ivanova, ^{2,3}Dinara Naizabayeva and ^{2,3}Andrey Zhigailov

¹Department of Veterinary Medicine Faculty of Veterinary Medicine and Animal Husbandry Technology, S. Seifullin Kazakh Agrotechnical Research University, Astana, Kazakhstan

²Almaty Branch of the National Center for Biotechnology, National Holding "QazBioPharm", Almaty, Kazakhstan

³M.A. Aitkhozhin Institute of Molecular Biology and Biochemistry, Ministry of Science and Higher Education of the Republic of Kazakhstan, Almaty, Kazakhstan

Article history

Received: 07-06-2024

Revised: 25-07-2024

Accepted: 27-07-2024

Corresponding Author:

Marina Kopochenya
Department of Veterinary
Medicine Faculty of Veterinary
Medicine and Animal
Husbandry Technology S.
Seifullin Kazakh Agrotechnical
Research University, Astana,
Kazakhstan
Email: Mgodgiven@mail.ru

Abstract: Although the NDV vaccination program is quite intensive in Kazakhstan, disease outbreaks are occurring repeatedly. During the fall season of 2023, we effectively achieved the isolation of the Newcastle Disease Virus (NDV) specifically, the class II genotype VII.2. This was accomplished in the context of an outbreak within industrial poultry layers located in the northern geographical sector of Kazakhstan. The employed methodology encompassed an exhaustive phylogenetic analysis of the fusion protein gene. This rigorous analytical process led to the definitive classification of the isolated virus under the category of NDV class II genotype VII.2. Yet the outbreak occurred despite highly qualitative on-farm vaccination against NDV. The study revealed that during the outbreak, serologic testing using both the Hemagglutinin Inhibition test (HI) test showed an increase of antibody titers in old layers ($10,3 \pm 2,6 \log_2$) and contrarily the fall of protective antibodies in young layers ($5,2 \pm 1,8 \log_2$), notwithstanding that before the outbreak, HI titers in all groups of layers were similar and amounted $8 \log_2$. Moreover, we conducted a pathological and microscopic examination of dead layers. We observed necrotic lesions, extensive hemorrhages, and congestion in various internal organs, indicating the infection with NDV virulent form. Histological analysis revealed vascular inflammation in the skin, eosinophilic endovasculitis, esophageal mucous membrane inflammation, larynx epithelium necrosis, and severe laryngeal swelling. This study highlights the first proven case of the VII.2 NDV strain in industrial birds in Kazakhstan, shedding light on the recurring outbreaks despite intensive vaccination. Veterinarians can use this information to detect NDV outbreaks early among vigorously vaccinated industrial birds.

Keywords: Genotype VII.2, Industrial Layers, Kazakhstan, Newcastle Disease Virus, Pathogenicity

Introduction

Newcastle Disease Virus (NDV) causes the disease manifesting in both domesticated and wild avian populations, underscoring its broad host range (Nooruzzaman *et al.*, 2022; Alexander and Senne, 2009). In spite of comprehensive immunization initiatives implemented within poultry establishments in Kazakhstan, the persistence of disease outbreaks continues to represent a substantial impediment for the nation's avian industry. This persistent challenge culminates in considerable economic deficits, thereby exacerbating the situation. In Kazakhstan, viscerotropic and neurotropic velogenic Newcastle disease viruses are

endemic and permanently provoke considerable economic loss. Factors like bird age, immune status, virus dosage, entry route, and environment notably affect NDV pathogenicity. Moreover, if the vaccine is not protective enough for chickens it is difficult to determine the NDV outbreak by the clinical signs only.

Significance of the Study

In Kazakhstan, poultry species such as layer and breeder chickens, characterized by extended lifespans, are subjected to immunization protocols involving both attenuated and killed vaccines. Live attenuated vaccines are administered as initial immunization during the pre-

production phase and are reapplied at intervals of approximately 1.5-2 months during the production phase. In contrast, killed vaccines are predominantly utilized at the onset of the production period, often in conjunction with vaccines for other significant pathogens. However, highly virulent ND strains still cause serious outbreaks in Kazakhstan poultry farms. Despite rigorous immunization initiatives, occurrences of Newcastle disease persistently manifest within the geographical boundaries of our nation.

Aim of the Study

The objective of this research was to explore the virus responsible for a recent outbreak in productive layers on a Kazakhstan farm, identify the outbreak's cause through serological, histopathological, and clinicopathological analyses, and characterize the virus on a molecular, phylogenetic, and pathotypic level.

Materials and Methods

The Farm, Microclimatic Conditions and Vaccination Program

The outbreak was registered in a commercial layers farm in the North of Kazakhstan. The farm contains 1,5 million layers of super nick cross and is one of the important egg producers in Kazakhstan's poultry industry. Each production birdhouse contains 75,000 layers. Birds are routinely vaccinated against ND both with live vaccines as primer vaccinations and inactivated vaccines as booster ones. Table (1) presents the scheme of ND vaccination on the farm. Poultry houses accommodating laying hens measure 18 by 102 m and are equipped with seven battery systems, each consisting of five tiers. The cage equipment, produced by the Specht company (Germany), houses 6 laying hens per cage with a feeding front of 60 cm. During the summer months, tunnel ventilation is employed in the poultry house, whereas supply and exhaust ventilation are utilized during winter. The ambient temperature is consistently maintained between +19 and +22 degrees Celsius, with a relative humidity of 65-75%. The lighting program in these industrial poultry houses adheres to a schedule of 9 h of light, with the remaining time in darkness. Water is sourced from a proprietary mine and undergoes reverse osmosis filtration. To deter wild birds, a gas repeller is deployed and food scatter is regulated. Rodenticide traps are strategically placed at intervals of 20-25 m for deratization, which is conducted every 10 days. Before occupancy, the poultry house undergoes a rigorous cleaning process. This begins with mechanical washing, followed by wet disinfection. Subsequently, laboratory control is performed to ensure cleanliness. The final step

involves aerosol disinfection using the hot fog method with glutaraldehyde, with an exposure period of 72 h. Birds are routinely vaccinated against ND both with live vaccines as primer vaccinations and inactivated vaccines as booster ones. Table (1) presents the scheme of ND vaccination on the farm.

Furthermore, all the birds were immunized against a range of pathogens, including Infectious Bursal Disease (IBD), Egg Drop Syndrome (EDS), Avian Pneumovirus (APV), Avian Encephalomyelitis (AE), and Avian Influenza (AI) subtype H5. These vaccinations were administered using vaccines produced by Boehringer Ingelheim (Germany), strictly adhering to the manufacturer's guidelines.

Outbreak

The outbreak started from a few deaths of young productive layers at the age of 160 days with respiratory signs. The number of deaths increased significantly every day, from 10 heads on day 1 to 300 heads on day 5 in each house. From the very beginning, there were no nervous signs neither typical hemorrhages nor necrosis in proventriculus. Furthermore, birds appeared to be depressed and lethargic with ruffled feathers and produced singing-like sounds. No deaths were registered among old productive layers but the production index decreased significantly. Two weeks later mass deaths were noticed in young rearing chickens with characteristic nervous signs and gross lesions in the intestinal tract.

Serological Testing

The HI antigen used in the study was manufactured by Royal GD Animal Health (Deventer, Netherlands) and procured from the local official distributor. The specific antigen catalog number is VLDIA039, strain La Sota. The Hemagglutination Inhibition (HI) assay was executed in adherence to a universally recognized methodology. A total of 322 serum samples underwent preliminary treatment with chicken erythrocytes to eliminate the potential for non-specific agglutination.

Table 1: Scheme of ND vaccination on the farm

Age of vaccination	Vaccine/ type/ strain	Route of vaccination
1 day	Avinew/live/VG/GA	Spray
22 days	Avinew/live/VG/GA	Spray
48 days	La Sota/live/La Sota	Spray
77 days	Avinew/live/VG/GA	Spray
95-100 days	Gallimune 407/inactivated/Ulster2C	Subcutaneous
Every 2 months during the production period	La Sota/live/La Sota	Spray

Autopsy and Pathological Analysis

Layers that succumbed during the designated observation period ($n = 254$) were promptly subjected to post-mortem examination. Macroscopic pathological changes in internal organs were documented through photographs. For viral detection, lung and trachea samples ($n = 25$) were collected aseptically and subjected to RT-PCR analysis using a previously described method (Saputri *et al.*, 2021). Moreover, tissue samples were analyzed histologically applying commonly known methods (Ewies *et al.*, 2017). All experimental procedures involving birds were executed meticulously in precise conformity with protocol #4 sanctioned by the local ethical committee on October 24, 2023. The protocol is valid for the period spanning from 2024-2026.

RNA Purification and Reverse Transcription

Viral ribonucleic acid was isolated from cloacal swab samples using trizol (Sigma). Complementary DNA (cDNA) was synthesized using M-MuLV reverse transcriptase (SibEnzyme, catalog no. E317) in line with the manufacturer's directives using random hexamer primers (Thermo Fisher Scientific, catalog no. SO142).

RT-PCR Assay

Conventional RT-PCR and direct sequencing of amplifications were used for laboratory confirmation of the Newcastle virus and its further genetic characterization. In the case of the L-gene locus, we used degenerate primers Paramyx_Pan-F1 (5'-GARGGNYDRTGYCARAARHTDTGGAC) and paramyx_Pan-R1 (5'-GCTGAAGTTACNGGHTCHCCDATRTTBC) which amplify a 657 bp fragment of the L-gene of avulaviruses. For the second PCR reaction, we used two pairs of NDV-specific inner primers developed by us, NDV-L-2173-nF3 (5'-TGGACKATGATCTCRATTGCWGC) and NDV-L-2783-nR3 (5'-GTRTAGAGCCTTGAGTATTGRAG) generating PCR-product of 611 bp. In the case of the second genetic locus, we used species-specific primers NDV-Fus-min57-F1 (5'-TTAGAAAAACACGGGTAGAA) and NDV-Fus-557-R1 (5'-AGTCGAGGATGTTGGCAGC) targeting Fus-gene of NDV and yielding an amplification product of 507 bp. Amplification was performed using Hot Start Taq DNA Polymerase (New England Biolabs, catalog no. MO495S) as per the manufacturer's guidelines. Each 25 μ L PCR reaction contained 2.5 μ L of the reverse transcription reaction product or 1.0 μ L of the 1st PCR product (in case of nested reaction). The temperature profile of PCR amplification was as follows: 95°C for 5

min, 94°C for 30 s, 55°C for 30 s, 72°C for 1 min; 40 cycles were performed followed by 5 min incubation at 72°C. The products derived from the polymerase chain reaction were subjected to analysis via electrophoresis on a 1.5% agarose gel, followed by visualization under ultraviolet illumination. After gel purification, PCR products of the expected size were sent to the Almaty Branch of the National Center for Biotechnology (AF NCB) for sequencing.

Sequencing and Phylogenetic Analysis

Purified PCR products were analyzed using a 24-capillary ABI 3500XL gene analyzer (applied biosystems, catalog no. A27856). Sequences were aligned using the MUSCLE algorithm. An unrooted phylogenetic tree was generated using the maximum likelihood algorithm using the MEGA X software. The bootstrap method with 1000 replicates was used to evaluate the reliability of the tree topologies.

Results

Serological Test Results

Every avian specimen within the agricultural establishment was immunized against Newcastle disease, employing both live and inactivated vaccine variants, in strict adherence to the prescribed immunization protocol. Permanently the layers were monitored for the ND immunity persistence using the HI test. Before the outbreak young productive layers had $7,9 \pm 1,2 \log_2$ in the HI test and old productive layers had $8,5 \pm 2,2 \log_2$ in the HI test.

All 322 layers' sera examined during the outbreak were identified as positive for antibodies against NDV. However, old productive layers showed an increase in HI titer $10,3 \pm 2,6 \log_2$, on the contrary, young productive layers had very low HI titers $5,2 \pm 1,8 \log_2$ during the outbreak.

Figures (1a-b) the kinetics of antibody response in layers vaccinated against Newcastle Disease Virus (NDV) and those naturally infected were quantified via Hemagglutination Inhibition (HI) assay. Serum samples were procured from 23 layers in each avian housing unit, both well in advance of and during the disease outbreak, concurrent with the observation of clinical symptoms and a decline in production indices.

The HI titers during the outbreak showed that young layers were more affected than old layers.

PCR and Phylogenetic Analysis Results

In order to confirm the presence of Newcastle Disease (ND) in the avian subjects, a nested Reverse Transcription Polymerase Chain Reaction (RT-PCR) was employed.

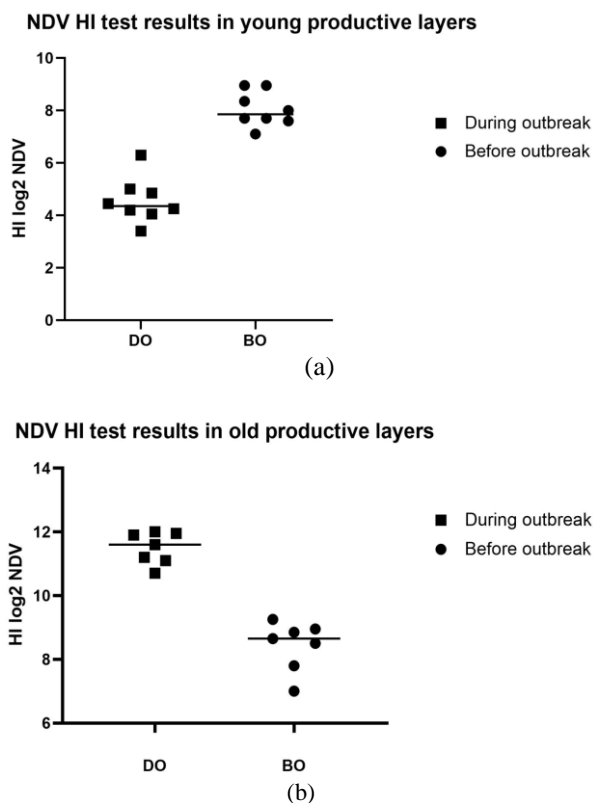


Fig. 1: Demonstrate the comparison between HI titers in young (a) and old (b) layers before and during the outbreak

This technique was chosen due to its ability to target the conservative viral polymerase L gene, making it suitable for detecting all known NDV lineages (Barman *et al.*, 2017). Furthermore, the direct sequencing of amplifications facilitated the genetic characterization of the virus, providing valuable insights into its genetic makeup. The choice of nested RT-PCR was also influenced by its increased sensitivity compared to a 1 step PCR, as documented in several scientific studies (Kim *et al.*, 2008; Kho *et al.*, 2000). This enhanced sensitivity allows for the detection of even low levels of the virus, increasing the accuracy of the diagnosis. In addition to the Nested RT-PCR, a one-step RT-PCR was used to amplify a partial F gene in five L-positive samples. The F gene locus was selected due to its inclusion of the F protein cleavage site, a critical determinant of viral virulence. The live Newcastle disease virus response aligns with its encapsulation in specific chitosan nanoparticles, as reported in carbohydrate polymers, 171, 267-280. [https://doi.org/10.1016/j.carbpol.2017.05.022]. The results of these tests were revealing. The L-gene of the Newcastle disease virus was identified in all five field samples collected from symptomatic birds using nested RT-PCR. However, when the one-step RT-PCR was

used, only two samples tested positive for the F gene (Fig. 2). Importantly, no amplification was observed in the negative control with either RT-PCR or nested PCR (Fig. 2), confirming the specificity of the tests.

PCR products corresponding to both the F-and L-genes were successfully obtained from sample #3, which was identified as the KZ03-2024-F0021W-NDV strain (Fig. 2). Following the amplification, these products were carefully eluted from the gel, a process that allows for their isolation and purification. Subsequently, these isolated products underwent direct sequencing in both directions, a technique that provides a comprehensive view of the genetic information contained within these genes. The sequences obtained from these partial F-and L genes were deemed significant enough to be deposited in GenBank, a comprehensive public database of genetic sequences. They have been assigned the accession numbers PP375638 and PP375639 respectively, providing researchers worldwide with access to this valuable genetic data.

The relationships among the sequences used in this study were determined based on the universal classification of NDVs, as proposed by Panda *et al.* (2004); Dimitrov *et al.* (2019). This classification system provides a standardized framework for comparing and categorizing NDV strains, facilitating the understanding of their genetic diversity and evolution. The phylogenetic analysis, a technique used to infer the evolutionary relationships between different organisms or genes, revealed that the KZ03-2024-F0021W-NDV strain belongs to the VII genotype (Fig. 3). This classification provides crucial insights into the genetic characteristics of this strain, which can guide future research and disease management strategies.

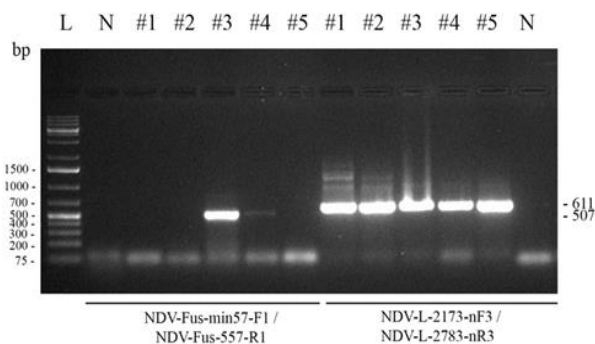


Fig. 2: Electrophoretic analysis of RT-PCR products generated from field NDV strain in 1.5% agarose gel using primers pairs NDV-Fus-min57-F/NDV-Fus-557-R1 and NDV-L-2173-nF3/NDV-L-2783-nR3. Lane L: 1 kb DNA ladder as molecular size marker; lane N: Negative control; lanes from #1-#5: Field samples

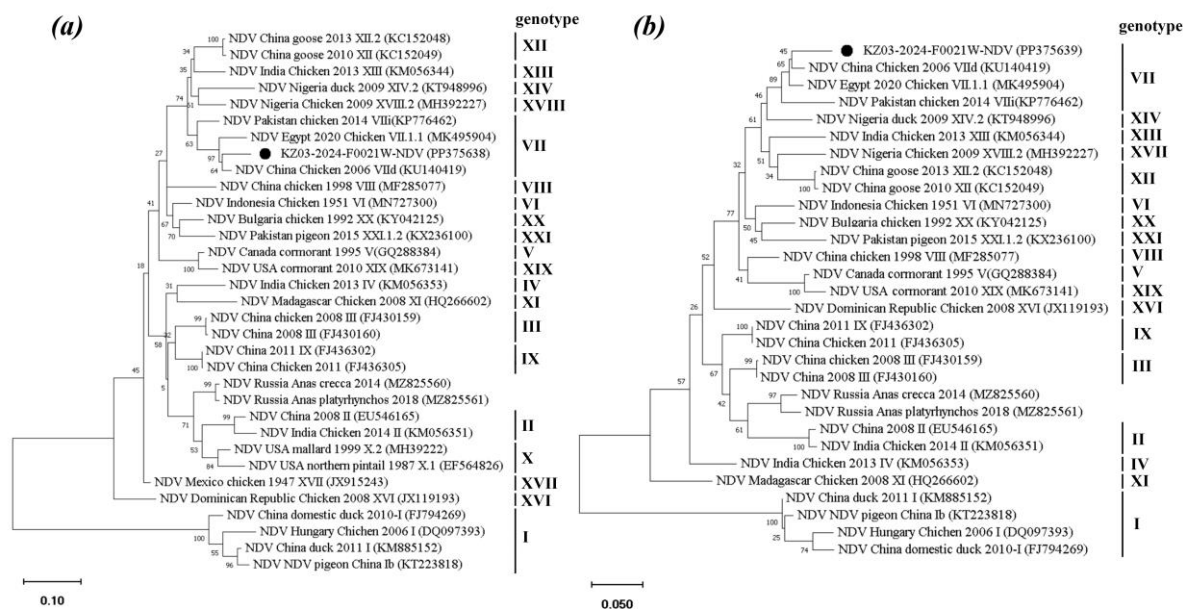


Fig. 3: A phylogenetic tree, constructed using the maximum likelihood method, of the KZ03-2024-F0021W-NDV strain, isolated in the course of this research (indicated by a black circle), alongside representative strains of NDV genotypes, is presented. The tree was generated based on partial sequences of the Fusion protein gene of NDV strains. The final dataset comprised a total of 459 positions. Bar: 0.10 changes per nucleotide position. (b) A phylogenetic tree based on L-gene sequences of NDV strains is shown. There was a total of 556 positions in the final dataset. Bar: 0.05 changes per nucleotide position. The construction of the phylogenetic tree was facilitated by the utilization of MEGA-X software. The proportion of trees, replicated in the bootstrap test (consisting of 1,000 replicates), in which the corresponding taxa were grouped together, is denoted at the nodes. Known NDV genotypes are presented to the right of the phylogenetic trees

Gross And Microscopic Lesions

The study revealed a correlation between the age of the layers and the severity of the gross lesions caused by infection. The younger layers displayed a more severe set of symptoms. These included bleeding in the trachea and lungs, indicative of respiratory distress, and hemorrhage in the proventricular glands, which could potentially affect digestion. Additionally, there were instances of intestinal ulcerations, which could lead to malabsorption and weight loss. Atrophy of the thymus and spleen was also observed, suggesting a possible impact on the immune response of these younger layers. In contrast, both younger and older layers showed hemorrhage in the cecal tonsils, an important part of the avian immune system, and a slight atrophy of the bursa of Fabricius, another crucial organ for immunity in birds. These symptoms suggest a systemic effect of the infection on the immune system of the layers, regardless of their age. These findings not only highlight the age-dependent severity of the infection but also suggest that younger layers may be more susceptible to severe clinical manifestations in response to NDV infection (Fig. 4).

Vivid changes are presented in Figs. (5-7) which were characteristic of the NDV in chicken.

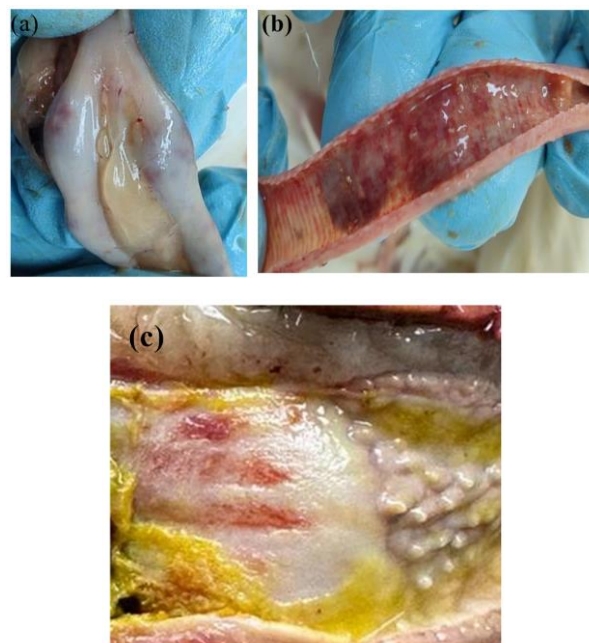


Fig. 4: (a) Button-like ulcerations present in the intestinal region; (b) Hemorrhagic occurrences within the trachea; (c) Pronounced bleedings in the proventriculus

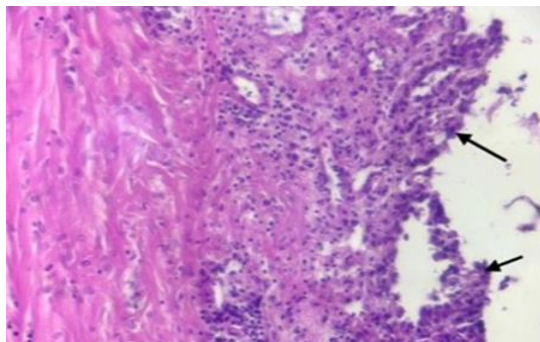


Fig. 5: Necrosis and desquamation of the epithelium of the larynx mucous membrane

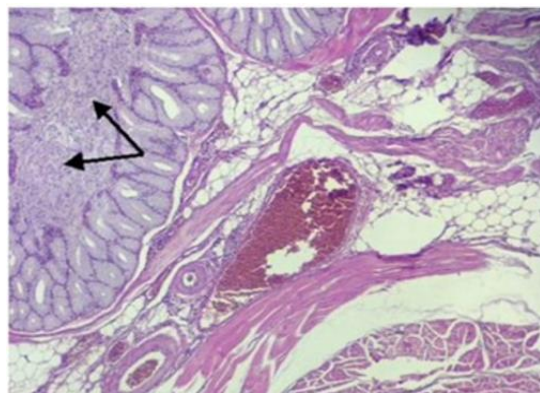


Fig. 6: Inflammatory hyperemia and edema of the esophagus mucous membrane

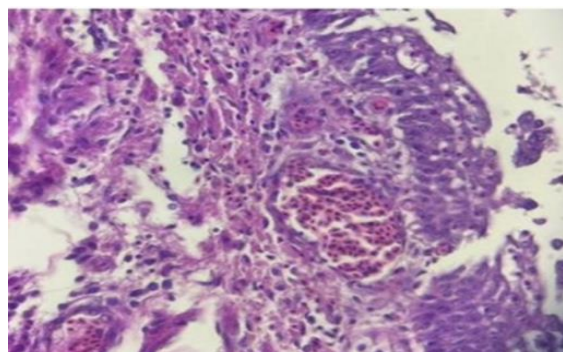


Fig. 7: Inflammatory hyperemia and swelling of the laryngeal mucosa

Moreover, inflammatory hyperemia of the vessels of the dermis of the skin and eosinophilic endovasculitis in the skin of the infected layers were observed.

Discussion

In the latter part of autumn 2023, an alarming outbreak of disease was reported on a poultry farm, leading to the untimely demise of over 200 birds within a span of 5 days. This occurred despite the prior administration of the

Newcastle Disease (ND) vaccine, raising serious concerns about its efficacy. The farm's proprietor reported this high mortality rate, necessitating an immediate and thorough investigation into the underlying cause.

Upon conducting a post-mortem examination of the birds that succumbed to the disease, several notable pathological findings were observed. These included the presence of hemorrhagic spots in specific regions of the birds' bodies, a characteristic indicative of a severe systemic infection. This manifestation is a classic symptom often associated with serious infectious diseases in avian species.

Further pathological investigation revealed additional abnormalities. There was noticeable hyperplasia, or abnormal increase in volume, of the hemorrhagic caecum tonsils. This is a significant finding as it suggests an aggressive immune response to a pathogen. Additionally, the formation of button-like ulcers in the intestinal tract was observed. These ulcers, often associated with severe gastrointestinal distress, further underscore the severity of the infection. These symptoms align closely with the clinical manifestations of Newcastle Disease (ND) in avian species. This correlation is supported by previous studies that have documented similar symptomatology in ND-affected birds (Eze *et al.*, 2013; Etriwati *et al.*, 2017). The diagnosis of ND was confirmed through a comprehensive approach encompassing clinical manifestations, pathological findings, serological tests, and molecular investigations. This was made possible by a state-funded research project. Molecular diagnostic techniques, despite their superior sensitivity and specificity for accurate diagnosis, necessitate substantial space, financial resources, and skilled personnel. Unfortunately, these resources are currently not readily available at the field level in Kazakhstan. This deficiency of advanced diagnostic tools may lead to delayed or inaccurate treatment of avian diseases, potentially resulting in significant economic losses for poultry farmers.

Newcastle Disease Virus (NDV) primarily invades respiratory epithelial cells, thereby inducing respiratory disorders (Ganar *et al.*, 2014). In the outbreak under investigation, a range of symptoms indicative of a severe systemic infection were observed. These included respiratory distress, a clear sign of compromised lung function, and the presence of button-like ulcers in the intestinal tract, suggesting significant gastrointestinal involvement. Other symptoms such as intratracheal bleeding, anterior ventricular bleeding, a runny nose, and a crowded trachea filled with exudates further highlighted the severity of the infection (Hussein *et al.*, 2019). Upon conducting further pathological investigations, a series of lesions were identified that provided additional insights into the nature of the disease. These included necrosis and desquamation of the laryngeal mucous epithelium, pointing to severe tissue damage in the larynx. Inflammatory

hyperemia, characterized by an increased blood flow due to inflammation and edema of the esophageal mucosa, indicating fluid accumulation in the esophageal tissues, was also observed. These findings paint a picture of a severe and systemic infection, affecting multiple organ systems and causing extensive tissue damage. The combination of these clinical symptoms and pathological findings strongly suggests the presence of a velogenic viscerotropic NDV strain. This strain is known for its virulence and its ability to cause severe disease in avian species, as evidenced by the extensive tissue damage and systemic symptoms observed in this outbreak.

Serological testing during the outbreak presented an unusual picture when compared to routine serological monitoring. The antibody titer recorded against NDV during routine monitoring at the farm ranged between 6,5-8,5 log₂, indicative of post-vaccination immunity against NDV. However, during the outbreak, the antibody titers in older productive layers showed a significant increase up to 10,3±2,6 log₂. Conversely, the serological titers of young productive layers fell to 5,2±1,8 log₂ during the outbreak. This discrepancy could be attributed to insufficient protection conferred by the ND vaccination (Twabela *et al.*, 2021) and subsequent depression of the immune response to the field NDV infection (Anis *et al.*, 2013; Zenglei and Liu, 2015).

The origin of the outbreak was traced back to the northern region of Kazakhstan. Through Polymerase Chain Reaction (PCR) testing and molecular sequencing, the pathogenic isolate was classified as a member of sub-genotype VII.2 of class II NDV. This constitutes the first documentation of this specific sub-genotype within the geographical confines of Kazakhstan. While the exact origin of Kazakhstan isolates remains unclear, the frequent importation of embryonated eggs and juvenile chickens from Russia suggests a possible pathway for introduction. The long-distance dispersion of NDV can be attributed to migratory avian species or inadvertent human activities (Wajid *et al.*, 2017; Marks *et al.*, 2014; Ferreira *et al.*, 2019). Considering the extensive migratory bird routes traversing Kazakhstan, this could potentially be a source of the newly identified NDV strain in the country (Turan *et al.*, 2020). However, this hypothesis warrants further investigation and confirmation.

Numerous factors may contribute to vaccine ineffectiveness during NDV outbreaks. These include inappropriate handling and administration of the vaccine, suboptimal conditions of vaccine storage, and the interference of maternal antibodies with the vaccine's efficacy. Moreover, the inherent capacity of the virus for mutation and evolution can lead to the emergence of novel strains potentially resistant to existing vaccines (Dimitrov *et al.*, 2021; Getabalew *et al.*, 2019; Hu *et al.*, 2022). These factors are particularly pertinent in large commercial farms with intensive production systems, highlighting the need for improved disease management strategies.

Conclusion

This study marks a significant milestone in the field of avian disease research, as it reports the first-ever detection of the velogenic Newcastle Disease Virus (NDV), specifically of the sub-genotype VII.2, in the country of Kazakhstan. The virus was isolated from commercial laying hens, a critical component of the country's poultry industry. The findings of our phylogenetic examination support the notion that the sub-genotype VII.2 NDV is circulating within the region. This is of particular concern as our observations highlight the potential of sub-genotype VII.2 viruses to instigate outbreaks, even in flocks that have been vaccinated. This raises questions about the efficacy of current vaccination strategies and underscores the need for further research into the underlying mechanisms of infection and potential vectors.

The implications of these findings are far-reaching, particularly for veterinarians working in industrial poultry farms. The comprehensive molecular, serological, pathological, and histological data provided in this study offer an invaluable resource for these professionals. This wealth of information will assist in the rapid recognition and diagnosis of NDV infection in vaccinated flocks, a situation where ND may not be initially suspected due to the assumed protection conferred by vaccination.

In conclusion, this study reveals sub-genotype VII.2 NDV's presence in Kazakhstan, emphasizing the need for ongoing research. The infection mechanism and vector are still unclear. As we learn more about NDV, we can improve disease management and protection, ensuring poultry health and industry stability.

Acknowledgment

The authors are grateful to Mr. Boris Mukhtarbekovich Ozdov for funding the research and for the research facilities.

Funding Information

This research was facilitated by the Ministry of Science and Higher Education of Kazakhstan [grant number AP23487052].

Author's Contributions

Marina Kopochenya: Contributed research ideas, data analysis, and manuscript preparation.

Belan Astemirov: Contributed to the original ideas of the research, research design, data collection data analysis, and interpretation.

Karina Ivanova: Contributed to the original ideas of the research and coordinated the manuscript preparation.

Dinara Naizabayeva: Contributed to data analysis and manuscript preparation.

Andrey Zhigailov: Contributed to the PCR, sequencing, and phylogenetic analysis and manuscript written.

Ethics

This article is original and contains unpublished material before. The authors declare that there are no ethical issues may arise after the publication of this study.

Conflict of Interest

The authors affirm that there are no known conflicts of interest associated with this publication and there has been no significant financial support for this study that could have influenced its outcome.

References

- Alexander, D. J., & Senne, D. A. (2009). *Diseases of Poultry* (A. M. Fadly, J. R. Glisson, L. R. McDougald, L. K. Nolan, & D. E. Swayne, Eds.; 12th Ed.). John Wiley & Sons.
- Anis, Z., Morita, T., Azuma, K., Ito, H., Ito, T., & Shimada, A. (2013). Histopathological Alterations in Immune Organs of Chickens and Ducks after Experimental Infection with Virulent 9a5b Newcastle Disease Virus. *Journal of Comparative Pathology*, 149(1), 82–93. <https://doi.org/10.1016/j.jcpa.2012.09.011>
- Barman, L. R., Nooruzzaman, M., Sarker, R. D., Rahman, Md. T., Saife, Md. R. B., Giasuddin, M., Das, B. C., Das, P. M., Chowdhury, E. H., & Islam, M. R. (2017). Phylogenetic Analysis of Newcastle Disease Viruses From Bangladesh Suggests Continuing Evolution of Genotype XIII. *Archives of Virology*, 162(10), 3177–3182. <https://doi.org/10.1007/s00705-017-3479-x>
- Dimitrov, K. M., Abolnik, C., Afonso, C. L., Albina, E., Bahl, J., Berg, M., Briand, F.-X., Brown, I. H., Choi, K.-S., Chvala, I., Diel, D. G., Durr, P. A., Ferreira, H. L., Fusaro, A., Gil, P., Goujgoulova, G. V., Grund, C., Hicks, J. T., Joannis, T. M., ... Wong, F. Y. K. (2019). Updated Unified Phylogenetic Classification System and Revised Nomenclature for Newcastle Disease Virus. *Infection, Genetics and Evolution*, 74, 103917. <https://doi.org/10.1016/j.meegid.2019.103917>
- Dimitrov, K. M., Taylor, T. L., Marcano, V. C., Williams-Coplin, D., Olivier, T. L., Yu, Q., Gogal, R. M., Suarez, D. L., & Afonso, C. L. (2021). Novel Recombinant Newcastle Disease Virus-Based In Ovo Vaccines Bypass Maternal Immunity to Provide Full Protection from Early Virulent Challenge. *Vaccines*, 9(10), 1189. <https://doi.org/10.3390/vaccines9101189>
- Etriwati, Ratih, D., Handharyani, E., & Setiyaningsih, S. (2017). Pathology and Immunohistochemistry Study of Newcastle Disease Field Case in Chicken in Indonesia. *Veterinary World*, 10(9), 1066–1071. <https://doi.org/10.14202/vetworld.2017.1066-1071>
- Ewies, S. S., Ali, A., Tamam, S. M., & Madbouly, H. M. (2017). Molecular characterization of Newcastle disease virus (genotype VII) from broiler chickens in Egypt. *Beni-Suef University Journal of Basic and Applied Sciences*, 6(3), 232–237. <https://doi.org/10.1016/j.bjbas.2017.04.004>
- Eze C. P., Okoye, J. O. A., Ogbonna, I. O., Ezema, W. S., EZE, D. C., Okwor, E. C., IBU, J. O., & Salihu, E. A. (2013). Comparative Study of the Pathology and Pathogenesis of a Local Velogenic Newcastle Disease Virus Infection in Ducks and Chickens. *International Journal of Poultry Science*, 13(1), 52–61. <https://doi.org/10.3923/ijps.2014.52.61>
- Ferreira, H. L., Taylor, T. L., Dimitrov, K. M., Sabra, M., Afonso, C. L., & Suarez, D. L. (2019). Virulent Newcastle Disease Viruses From Chicken Origin Are More Pathogenic and Transmissible to Chickens Than Viruses Normally Maintained in Wild Birds. *Veterinary Microbiology*, 235, 25–34. <https://doi.org/10.1016/j.vetmic.2019.06.004>
- Ganar, K., Das, M., Sinha, S., & Kumar, S. (2014). Newcastle Disease Virus: Current Status and Our Understanding. *Virus Research*, 184, 71–81. <https://doi.org/10.1016/j.virusres.2014.02.016>
- Getabalew, M., Akeberegn, D., Alemneh, T., & Zewdie, D. (2019). Epidemiology, Diagnosis & Prevention of Newcastle Disease in Poultry. *American Journal of Biomedical Science & Research*, 3(1), 50–59. <https://doi.org/10.34297/AJBSR.2019.03.000632>
- Hu, Z., He, X., Deng, J., Hu, J., & Liu, X. (2022). Current Situation and Future Direction of Newcastle Disease Vaccines. *Veterinary Research*, 53(1), 99. <https://doi.org/10.1186/s13567-022-01118-w>
- Hussein, E. A., Hair-Bejo, M., Omar, A. R., Arshad, S. S., Hani, H., Balakrishnan, K. N., Yakubu, Y., Saeed, M. I., & Aini, I. (2019). Velogenic Newcastle Disease Virus Tissue Tropism and Pathogenesis of Infection in Chickens by Application of in Situ Pcr, Immunoperoxase Staining and He Staining. *Microbial Pathogenesis*, 129, 213–223. <https://doi.org/10.1016/j.micpath.2019.02.017>
- Kho, C. L., Mohd-Azmi, M. L., Arshad, S. S., & Yusoff, K. (2000). Performance of an RT-nested PCR ELISA for detection of Newcastle disease virus. *Journal of Virological Methods*, 86(1), 71–83. [https://doi.org/10.1016/s0166-0934\(99\)00185-8](https://doi.org/10.1016/s0166-0934(99)00185-8)

- Kim, L. M., Suarez, D. L., & Afonso, C. L. (2008). Detection of a Broad Range of Class I and II Newcastle Disease Viruses Using a Multiplex Real-Time Reverse Transcription Polymerase Chain Reaction Assay. *Journal of Veterinary Diagnostic Investigation*, 20(4), 414–425.
<https://doi.org/10.1177/104063870802000402>
- Marks, F. S., Rodenbusch, C. R., Okino, C. H., Hein, H. E., Costa, E. F., Machado, G., Canal, C. W., Brentano, L., & Corbellini, L. G. (2014). Targeted Survey of Newcastle Disease Virus in Backyard Poultry Flocks Located in Wintering Site for Migratory Birds From Southern Brazil. *Preventive Veterinary Medicine*, 116(1–2), 197–202.
<https://doi.org/10.1016/j.prevetmed.2014.06.001>
- Nooruzzaman, M., Hossain, I., Begum, J. A., Moula, M., Khaled, S. A., Parvin, R., Chowdhury, E. H., Islam, M. R., Diel, D. G., & Dimitrov, K. M. (2022). The First Report of a Virulent Newcastle Disease Virus of Genotype VII.2 Causing Outbreaks in Chickens in Bangladesh. *Viruses*, 14(12), 2627.
<https://doi.org/10.3390/v14122627>
- Panda, A., Huang, Z., Elankumaran, S., Rockemann, D. D., & Samal, S. K. (2004). Role of Fusion Protein Cleavage Site in the Virulence of Newcastle Disease Virus. *Microbial Pathogenesis*, 36(1), 1–10.
<https://doi.org/10.1016/j.micpath.2003.07.003>
- Saputri, M., Poetri, O., & Soejoedono, R. (2021). Phylogenetic Studies of Newcastle Disease Virus Isolated From Poultry Flocks in South Sulawesi Province, Indonesia, in 2019. *Journal of Advanced Veterinary and Animal Research*, 8(1), 129.
<https://doi.org/10.5455/javar.2021.h495>
- Turan, N., Ozsemir, C., Yilmaz, A., Cizmecigil, U. Y., Aydin, O., Bamac, O. E., Gurel, A., Kutukcu, A., Ozsemir, K., Tali, H. E., Tali, B. H., Yilmaz, S. G., Yaramanoglu, M., Tekelioğlu, B. K., Ozsoy, S., Richt, J. A., Iqbal, M., & Yilmaz, H. (2020). Identification of Newcastle disease virus subgenotype VII.2 in wild birds in Turkey. *BMC Veterinary Research*, 16(1), 1–8.
<https://doi.org/10.1186/s12917-020-02503-3>
- Twabela, A. T., Nguyen, L. T., Masumu, J., Mpyoyo, P., Mpiana, S., Sumbu, J., Okamatsu, M., Matsuno, K., Isoda, N., Zecchin, B., Monne, I., & Sakoda, Y. (2021). A New Variant among Newcastle Disease Viruses Isolated in the Democratic Republic of the Congo in 2018 and 2019. *Viruses*, 13(2), 151.
<https://doi.org/10.3390/v13020151>
- Wajid, A., Dimitrov, K. M., Wasim, M., Rehmani, S. F., Basharat, A., Bibi, T., Arif, S., Yaqub, T., Tayyab, M., Ababneh, M., Sharma, P., Miller, P. J., & Afonso, C. L. (2017). Repeated isolation of virulent Newcastle disease viruses in poultry and captive non-poultry avian species in Pakistan from 2011-2016. *Preventive Veterinary Medicine*, 142, 1–6.
<https://doi.org/10.1016/j.prevetmed.2017.04.010>
- Zenglei, H., & Liu, X. (2015). Immune response-induced NDV pathology. *British Journal of Virology*, 2(2), 25–27.